



## Dietary Habits Affect Quality of Life: Bowel Obstruction Caused by Phytobezoar

**Majid AKRAMI<sup>1</sup>, \*Mohammad Reza SASANI<sup>2</sup>**

1. Dept. of Surgery, Shiraz University of Medical Sciences, Shiraz, Iran
2. Medical Imaging Research Center, Dept. of Radiology, Shiraz University of Medical Sciences, Shiraz, Iran

\*Corresponding Author: Email: sasanimr@sums.ac.ir

(Received 12 Dec 2015; accepted 24 Apr 2016)

### Abstract

Nutritional status is very important especially in older adults because of its effects on quality of life. Phytobezoar, for instance, that can lead to small bowel obstruction has risk factors such as excessive consumption of foods with high fiber content and inadequate chewing. These factors are related to dietary habits. Furthermore, aging process and some of related physiologic changes can predispose one to phytobezoar formation. We describe a 61-yr-old man presented to the Emergency Department of Nemazee Hospital, Shiraz University of Medical Sciences, Shiraz, Iran, in 2015 with small bowel obstruction due to phytobezoar following large amount of pomegranate seeds intake a few days before admission as an example of increased morbidity relating to unusual dietary habit.

**Keywords:** Aging, Bezoars, Intestinal obstruction, Nutritional status, Physiological process

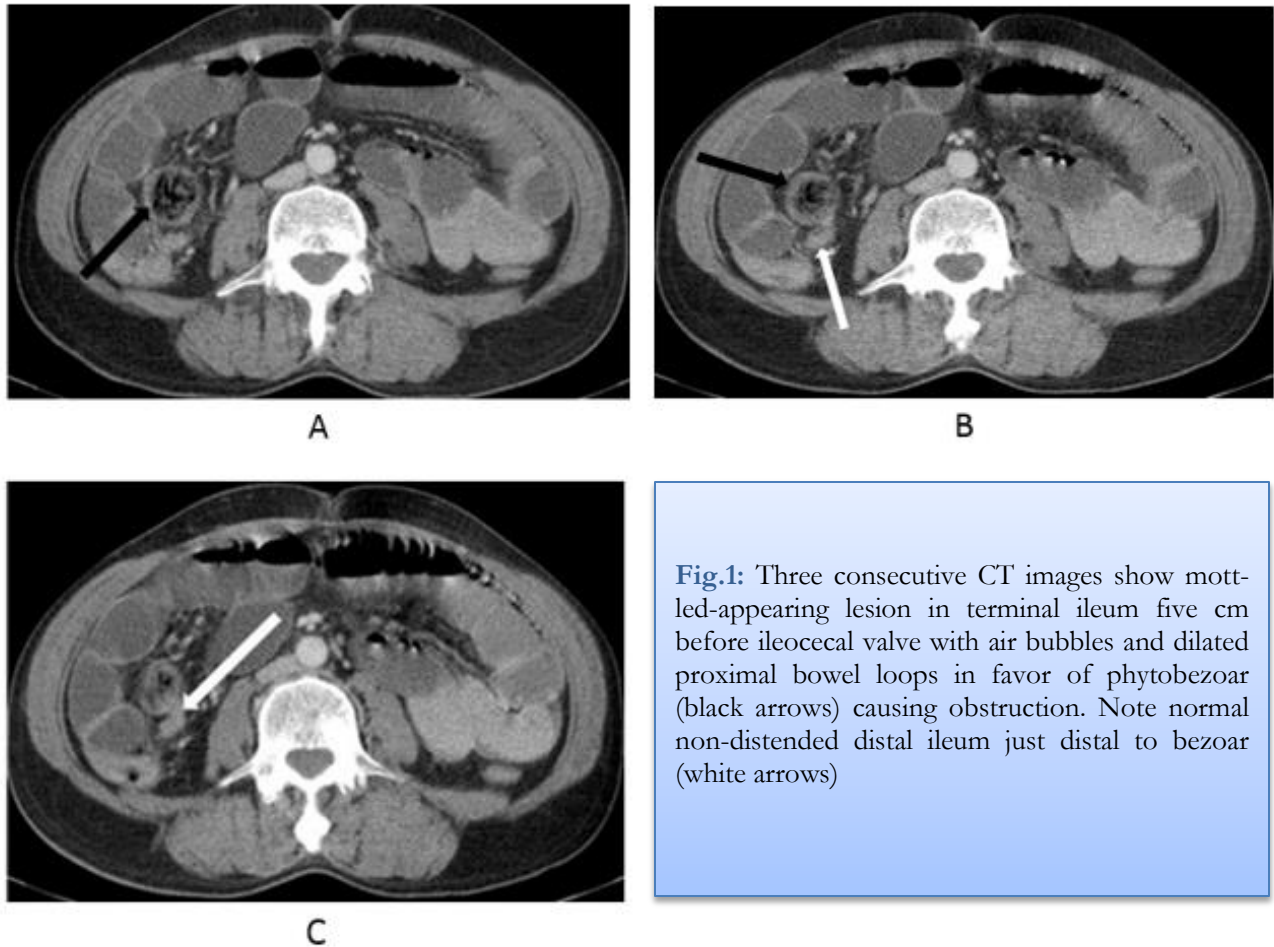
### Introduction

Nutritional status is very important especially in old age population because any imbalance in nutritional status has negative effect on quality of life and causes increase morbidity and mortality. For instance, phytobezoar, a bezoar consist of fruit and vegetable fibers, can lead to small bowel obstruction and has risk factors such as intake of large amount of food with high-fiber content and inadequate chewing (1, 2). These factors are partly related to dietary habits. Furthermore, aging process and some of related physiologic changes can predispose one to phytobezoar formation. We describe a case of small bowel obstruction due to phytobezoar following large amount of pomegranate seeds intake a few days before admission as an example of increased morbidity relating to unusual dietary habit.

### Case Report

A 61 year-old man was admitted to Emergency Department of Nemazee Hospital, Shiraz Uni-

versity of Medical Sciences, Shiraz, Iran, in 2015 with bowel obstruction. Abdominal radiographs revealed dilated small-bowel loops and multiple air-fluid levels. CT scan showed a mottled-appearing lesion in terminal ileum with air bubbles and dilated proximal bowel loops (Fig. 1). Because our patient had consumed large amount of pomegranate seeds five days before admission and with no history of previous abdominal surgery, phytobezoar became first diagnosis as cause and scheduled for surgery. During laparotomy, there were impacted materials in favor of phytobezoar just before ileocecal valve causing complete obstruction of small-bowel. The blockage resolved with pushing the intestinal contents into large bowel. The patient was discharged after passing unremarkable postoperative course and was doing well at two months follow up visit. An informed consent was obtained from the patient.



**Fig.1:** Three consecutive CT images show mottled-appearing lesion in terminal ileum five cm before ileocecal valve with air bubbles and dilated proximal bowel loops in favor of phytobezoar (black arrows) causing obstruction. Note normal non-distended distal ileum just distal to bezoar (white arrows)

## Discussion

Nutritional status is very important especially in old age population because any imbalance in nutritional status has negative effect on quality of life and causes increase morbidity and mortality. One of the problems relating to dietary habit is phytobezoar formation in the gastrointestinal tract. Bezoars are masses produced by accumulation of undigested material such as fruit, hair, and milk in gastrointestinal tract more frequently in stomach (3, 4) and one of the most common types of bezoar is phytobezoar (5), composed of fruit and vegetable fibers. Phytobezoar as a cause of small bowel obstruction has risk factors such as intake of large amount of food with high-fiber content and inadequate chewing (1, 2). Excessive consumption of foods with high fiber content is a dietary factor. Inadequate chewing can result of

dental problems such as difficult chewing following loss of teeth that frequently seen in older age group (6). Moreover, inadequate chewing in part is related to habits. Other factor in aging population is loss of intestinal elasticity, as a physiologic change commonly seen in this group, and resultant constipation (6) may be considered as another reason for increased chance of intestinal phytobezoar formation. In other words, intestinal phytobezoar formation is a multifactorial entity, involving dietary and alimentary factors (7) and dental hygiene. Therefore, good dietary habit and proper dental hygiene in lifetime are necessary for maintaining a healthy population especially in older adults.

Small bowel obstruction is another area for consideration that is a common disease and result from many causes such as adhesion, hernia, inflammation, tumor and bezoar. Two to three

percent of small bowel obstructions are due to bezoar (7). In addition, most frequent manifestation of bezoar is complete intestinal obstruction (8) and computed tomography is useful in its diagnosis (1). Findings of bezoar-induced small bowel obstruction on CT scan are intraluminal mass containing air bubbles and dilated bowel loops proximal to mass and normal distal loops (1).

The dietary habit of having large amount of vegetables and fruit in Asian countries can be result in phytobezoar formation as relatively common cause of small bowel obstruction in the absence of previous gastric surgery (4). Small bowel obstruction due to bezoar may need surgery for treatment and this entity rarely improves with conservative therapy, hence it is important to consider this diagnosis as the reason for obstruction (1). In this way, in patients with small bowel obstruction that have history of recent consumption of vegetables or food with high fiber content and no past history of surgery, phytobezoar should be kept in mind with high index of suspicion.

### Ethical considerations

Ethical issues (including plagiarism, informed consent, misconduct, data fabrication and/or falsification, double publication and/or submission, redundancy, etc.) have been completely observed by the authors.

### Acknowledgments

Authors declare that they have no conflict of interest.

### References

1. Ripolles T, Garcia-Aguayo J, Martinez MJ, Gil P (2001). Gastrointestinal bezoars: sonographic and CT characteristics. *AJR Am J Roentgenol*, 177 (1): 65-9.
2. Chen YC, Liu CH, Hsu HH, Yu CY, Wang HH, Fan HL, et al. (2015). Imaging differentiation of phytobezoar and small-bowel faeces: CT characteristics with quantitative analysis in patients with small-bowel obstruction. *Eur Radiol*, 25 (4): 922-31.
3. Oh SH, Namgung H, Park MH, Park DG (2012). Bezoar-induced Small Bowel Obstruction. *J Korean Soc Coloproctol*, 28 (2): 89-93.
4. De Cesare A, Fiori E, Bononi M, Ferraro D (2015). Phytobezoar-induced small bowel obstruction associated with a concomitant gastric phytobezoar and ulcer in an elderly woman. *Ann Ital Chir*, 86 (1): 70-7.
5. Zissin R, Osadchy A, Gutman V, Rathaus V, Shapiro-Feinberg M, Gayer G (2004). CT findings in patients with small bowel obstruction due to phytobezoar. *Emerg Radiol*, 10 (4): 197-200.
6. Kathryn E Brogan, K-L Catherine Jen (2010). *Nutrition in the Elderly. In: Handbook of assessment in clinical gerontology*. Ed, Peter A Lichtenberg. 2<sup>nd</sup> ed, Elsevier Inc, pp. 357-359.
7. Bedioui H, Daghfous A, Ayadi M, Noomen R, Chebbi F, Rebai W, et al. (2008). A report of 15 cases of small-bowel obstruction secondary to phytobezoars: predisposing factors and diagnostic difficulties. *Gastroenterol Clin Biol*, 32 (6-7): 596-600.
8. Escamilla C, Robles-Campos R, Parrilla-Paricio P, Lujan-Mompean J, Liron-Ruiz R, Torralba-Martinez JA (1994). Intestinal obstruction and bezoars. *J Am Coll Surg*, 179 (3): 285-8.