



## **Intraventricular Hemorrhage in a Term Neonate: Manifestation of Protein S Deficiency- A Case Report**

**Shahriar SAHRIARIAN<sup>1</sup>, Parvin AKBARI<sup>1</sup>, Elahe AMINI<sup>2</sup>, Hosein DALILI<sup>2</sup>, Tahereh ESMAEILNIA SHRIVANY<sup>1</sup>, Nikoo NIKNAFS<sup>1</sup>, Mamak SHARIAT<sup>1</sup>, \*Vafa GHORBAN SABAGH<sup>1</sup>**

1. *Maternal-Fetal-Neonatal Research Center, Tehran University of Medical Sciences, Tehran, Iran*
2. *Breastfeeding Research Center, Tehran University of Medical Sciences, Tehran, Iran*

**\*Corresponding Author:** Email: Dr.Sabagh@yahoo.com

(Received 21 Nov 2015; accepted 12 Jan 2016)

### **Abstract**

Protein S (PS) is an antithrombotic plasma protein that plays essential roles in limiting thrombus formation in the anticoagulant system. Protein S deficiency is related with recurrent thrombosis. Here, the authors report a case of a term neonate with severe PS deficiency in year 2015, Imam Hospital, Tehran, Iran, that had seizures and intraventricular hemorrhage (IVH) since the age of 3 days. Nine-month follow-up did not show any developmental problems and MRI showed no hemorrhage.

**Keywords:** Intraventricular hemorrhage, Protein S deficiency

### **Introduction**

Protein S (PS) is an antithrombotic plasma protein that acts mainly as a cofactor of activated protein C (APC) anticoagulant activity in the degradation of factor Va and activated factor VIII(1). PS deficiency is a hereditary autosomal dominant disorder, described in 1984 in several cases with low level of protein S and A outstanding history of recurrent thrombosis (2). Findings show in healthy individuals, approximately 60% of PS is bound in a complex with C4b-binding protein (C4bBP) that is a regulatory factor of the complement system. Only the remaining 40% of PS is capable to be a cofactor for APC (3). PS deficiency is an infrequent but harsh hereditary thrombophilic disorder with a prevalence of between 0.03% and 0.13% in the general population (2, 4). Main symptoms of PS deficiency are superficial thrombophlebitis, deep venous thrombosis and

pulmonary emboli (5). In the present study the authors describe a case of a term neonate with severe PS deficiency that had seizures and intraventricular hemorrhage (IVH) since the age of 3 days.

### **Case Report**

A 31-yr-old woman has delivered a term female infant with 40wk of gestational age. The newborn Apgar score in ten min after delivery was 7, the newborn weight was 4000 g. Because of progression of jaundice at the first day of life baby was admitted to the Imam Hospital, Tehran, Iran, in yr 2015.

Parents filled an informed consent to be involved in this study. All information remained secret and no clear picture of newborn was published.

The primary physical examination showed no abnormalities. On the 3rd day of life, newborn was transferred to the Neonatal Intensive Care Unit of Imam Hospital, because of seizures. Despite phenobarbital administration, the seizures persisted. No sign of infections and metabolic disorders were found in the test results and the spleen and liver were not palpable. Brain MRI showed diffuse periventricular and intraventricular hemorrhage on both sides. The internal cerebral vein was dilated and a small number of irregular vessels in the mid sagittal region were observed. Acute ischemic foci (limited on DWI) were observed in both genu of the corpus callosum and in the frontal lobes as well. Ventricular dilatation was acknowledged too. Brain MR-angiography (MRA) revealed that main intracranial vascular structure was normal (Fig.1). A few days later, Grade 1 intraventricular hemorrhage was extended to Grade 2 and 3 hemorrhages; sonography of the brain showed Grade 2 intraventricular hemorrhage in the right and Grade 3 in the left side. Head circumference

was not obviously increased from the initial measurement. Moreover, mobile masses in the inferior vena cava (IVC), protruding into the right atrium (RA) and multiple thrombosis of the portal vein were reported in neonatal echocardiography (Fig. 2). Metabolic profile (including homocysteine, ammonia, and lactate) and plasma amino acid level were normal. The blood concentration of antithrombin III, fibrinogen, protein C and factor V Leiden were within normal ranges. The study revealed the quick decrease of protein S in the infant's blood while the parent's samples were normal.

Thrombocytopenia was shown in the history of pregnancy, and the mother had been treated with dexamethasone. She was the first offspring of a consanguineous marriage. Fresh frozen plasma was infused at that time. Aspirin therapy was continued, leading to the improvement of the infant condition. During the nine-month follow-up, the infant did not show any developmental problems and MRI revealed no hemorrhage.

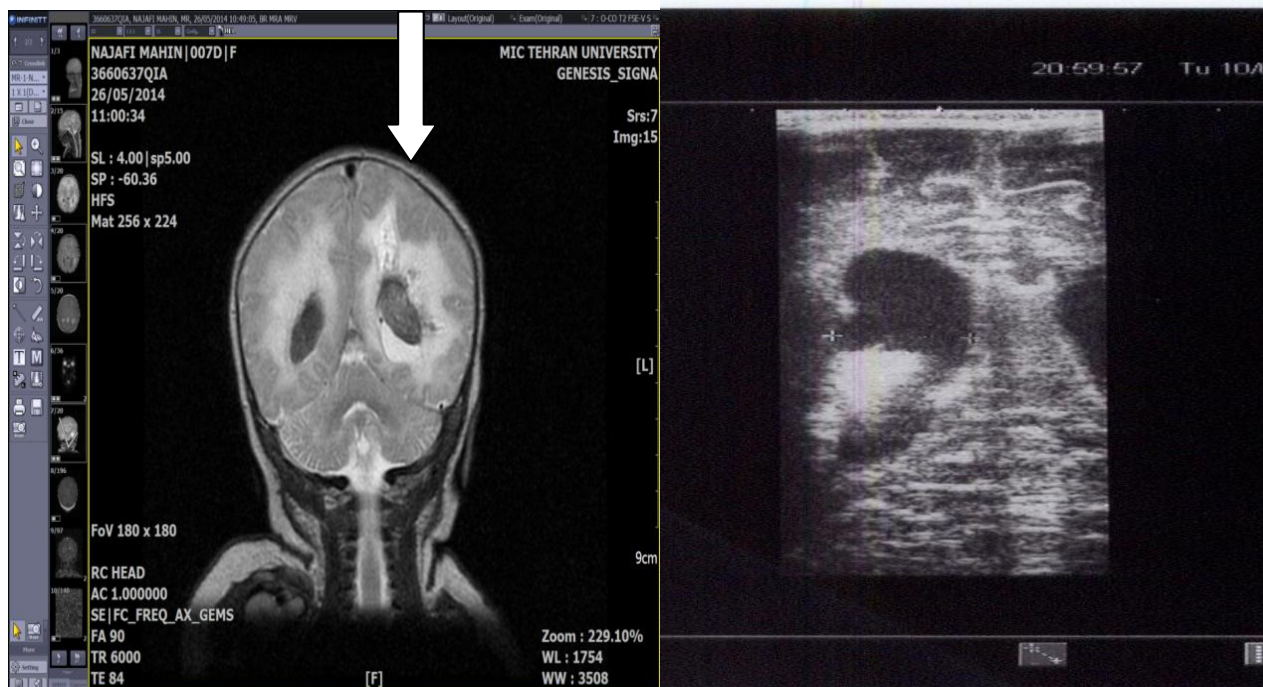
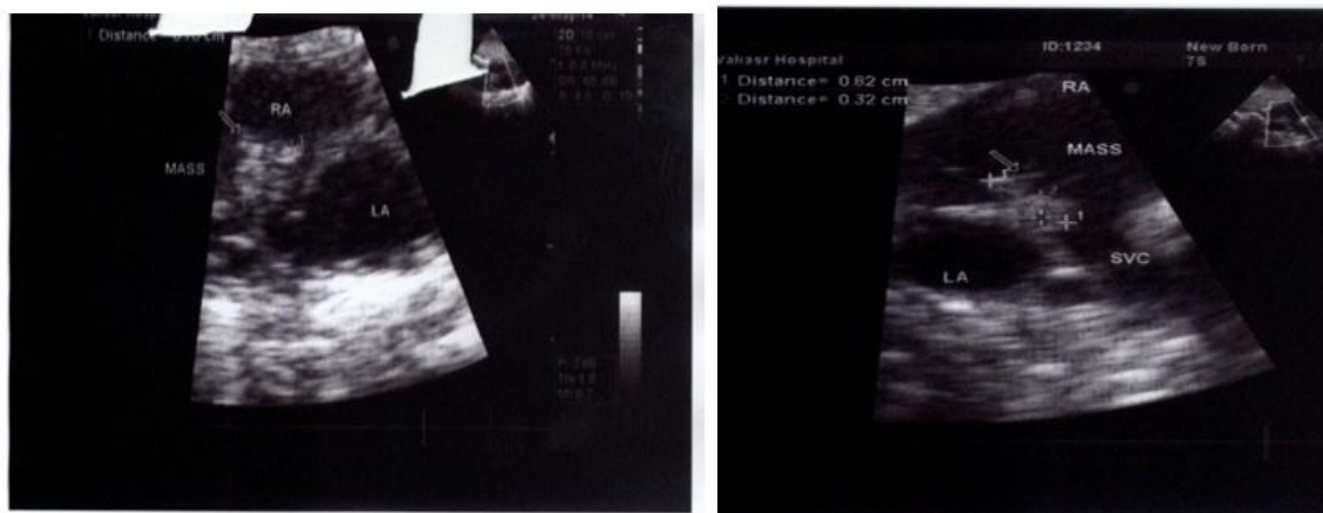


Fig. 1: MRI and Sonography on 3d day of life. Intraventricular hemorrhage and AV malformation (MRV)



**Fig. 2:** SVC thrombosis (right) and thrombus in the right atrium (left)

## Discussion

Seizures happen more frequently during the neonatal period compared with any other period of the human lifetime. Population based studies recommend that the incidence of seizures in term newborns is 1 to 3 per 1000 live births (6). Generally, clinical diagnosis of neonatal seizures is difficult, since seizures are usually not accompanied by any particular clinical symptoms (7, 8).

On the other hand, the relationship between hereditary thrombotic disease and deficiencies of protein C and protein S is distinguished. We described a case of a term neonate with seizures, mobile masses in the IVC, IVH, and multiple thrombosis of portal vein due to decline in PS level. Because of the normal level of protein S in the parents, and in the infant as well, in the period of the follow-up, it appears that the protein S deficiency in this infant was temporary and as a result of A-V malformation.

To our knowledge, just a concise similar case-report has been published. Comp et al. (2, 9) described two patients that had a double heterozygous or homozygous deficiency of protein S. Fischer et al. (10) reported a newborn with homozygous qualitative PS deficiency who had a

PS plasma activity <10% and intracerebral massive bleeding. Moreover, hemorrhagic ischemic stroke with protein S deficiency and thrombosis were reported in young patients (11-13).

In preterm neonates, IVH is observed mainly in the context of germinal matrix hemorrhage. On the contrary, in the term of neonates, IVH initially occurs as a result of hemorrhage in the choroid plexus or thalamus (14, 15). The long-term prognosis of PS deficiency after IVH in term newborns is ambiguous (16). Long-term follow-up is necessary to find out the predictors of neurological sequelae after IVH in term newborns.

## Ethical considerations

Ethical issues (Including plagiarism, informed consent, misconduct, data fabrication and/or falsification, double publication and/or submission, redundancy, etc.) have been completely observed by the authors.

## Acknowledgement

The authors declare that there is no conflict of interests.

## Reference

1. Walker FJ (1981). Regulation of activated protein C by protein S. The role of phospholipid in factor Va inactivation. *J Biol Chem*, 256 (21):11128-31.
2. Comp P, Nixon RR, Cooper M, Esmon C (1984). Familial protein S deficiency is associated with recurrent thrombosis. *J Clin Invest*, 74 (6):2082-8
3. Mizukami K, Nakabayashi T, Naitosh S, Takeda M, Tarumi T, Mizoguchi I, Ieko M, Koike T (2006). One novel and one recurrent mutation in the PROS1 gene cause type I protein S deficiency in patients with pulmonary embolism associated with deep vein thrombosis. *Am J Hematol*, 81 (10):787-97.
4. Dykes AC, Walker ID, McMahon AD, Islam S, Tait R (2001). A study of Protein S antigen levels in 3788 healthy volunteers: influence of age, sex and hormone use, and estimate for prevalence of deficiency state. *Br J Haematol*, 113 (3):636-41.
5. Azarpeikan S, Hashemi A, Atefi A (2011). Lacunar infarction in child with Protein S deficiency: A case report. *Iran J Ped Hematol Oncol*, 1 (2):67-70.
6. Glass HC, Kan J, Bonifacio SL, Ferriero DM (2012). Neonatal seizures: treatment practices among term and preterm infants. *Pediatr Neurol*, 46 (2):111-15.
7. El-dib M, Chang T, Tsuchida TN, Clancy RR (2009). Amplitude-integrated electroencephalography in neonates. *Pediatr Neurol*, 41 (5):315-26.
8. Murray DM, Boylan GB, Ali I, Ryan CA, Murphy BP, Connolly S (2008). Defining the gap between electrographic seizure burden, clinical expression and staff recognition of neonatal seizures. *Arch Dis Child Fetal Neonatal Ed*, 93 (3):F187-91.
9. Comp P (1986). Hereditary disorders predisposing to thrombosis. *Prog Hemost Thromb*, 8:71.
10. Fischer D, Porto L, Stoll H, Geisen C, Schloesser RL (2010). Intracerebral mass bleeding in a term neonate: manifestation of hereditary protein S deficiency with a new mutation in the PROS1 gene. *Neonatology*, 98(4):337-40.
11. Sabzi F, Faraji R (2013). Right atrial thrombosis associated with sagittal sinus thrombosis caused by protein C-S deficiency. *JNMA J Nepal Med Assoc*, 52 (190): 378-83.
12. Sultan A, Malik IH (2013). Recurrent Cerebral Infarctions in a Young Patient: Combined Protein C and S Deficiencies. *J Coll Physicians Surg Pak*, 23 (10):813-14.
13. Sen K, Adhikari A, Biswas S, Chattopadhyey J, Pandey U (2012). Lateral sinus thrombosis and haemorrhagic ischemic stroke with protein S deficiency in a young. *Nepal Med Coll J*, 14 (3):263-64.
14. Scher MS, Wright FS, Lockman LA, Thompson TR (1982). Intraventricular Hemorrhage in Full-term Neonates. *Arch Neurol*, 39(12):769-72.
15. Roland EH, Flodmark O, Hill A (1990). Thalamic hemorrhage with intraventricular hemorrhage in the full-term newborn. *Pediatrics*, 85 (5):737-42.
16. Scher MS, Wright FS, Lockman LA, Thompson TR (1982). Intraventricular hemorrhage in the full-term neonate. *Arch Neurol*, 39 (12):769-72.