



Interventricular Septum Hydatid Cyst: Successful Seven-Year Follow Up- Case Report

*Asadollah MIRZAI¹, Majid Reza ERFANIAN-TAGHVAEI², *Maryam MIRZAI³,
Reza SHARIFI-NOGHABI⁴*

1. Dept. of Cardiac Surgery, Mashhad University of Medical Sciences, Mashhad, Iran
2. Dept. of Community Medicine, Mashhad University of Medical Sciences, Mashhad, Iran
3. Dept. of Community Medicine, Mashhad University of Medical Sciences, Mashhad, Iran
4. Dept. of General Surgery, Gonabad University of Medical Sciences, Gonabad, Iran

***Corresponding Author:** Email: Maryam_mirzaie@hotmail.com

(Received 15 Jun 2014; accepted 21 July 2014)

Abstract

Hydatid cyst disease should be considered in differential diagnosis in many doubtful clinical situations as can present with non-specific symptoms especially in the endemic areas. Cardiac involvement should be considered in patients with history of previous hydatid cyst disease.. Cardiac hydatid cysts account for less than 2% of all hydatid diseases. In this report we aimed to present a case of 14-year-old boy with the diagnosis of occlusion of artery of the right lower extremity. Surgical exploration of the femoral artery revealed multiple hydatid cysts. Echocardiography showed a mobile mixed mass lesion. Complete resection of the mass was done from interventricular septum. Histopathological examination of the removed tissue revealed a complicated hydatid cyst and complete mass excision was confirmed. In this case a 7 year clinical and serological tests evaluation follow-up after surgical treatment showed no evidence of recurrence. The finding of this case emphasizes that in endemic countries, primary cardiovascular echinococcosis should be considered in differential diagnosis.

Keywords: Echinococcosis, Interventricular Septum, Embolism

Introduction

Hydatidosis due to the cestode *Echinococcus granulosus* is a disease reported globally, but it is endemic in Asia, the Middle East, North Africa and Australia. It is especially far more frequent in Mediterranean countries (1, 2).

The adult taenia lives in the small intestine of carnivores such as dogs, foxes, and wolves as the main host. Taenia eggs are excreted in the feces of these animals and either directly or by contamination of plants, fruits or vegetables, enters the gut of herbivores where the enzymes dissolve the eggs and the larvae are released (3). The parasite again enters the main host as these contaminated ani-

mals are eaten by carnivores. Man is an intermediate or accidental host of this parasite, and is infected by consuming contaminated plants or vegetables, or by contact with dogs (4). *Echinococcus* produce cysts and implant in different organs. Cardiac hydatid cysts are extremely rare (5, 6). Although patients may remain asymptomatic for many years or have only mild nonspecific symptoms, they might experience life-threatening complications. But since the cyst grows very slowly the disease is diagnosed with long delays after infection.

Case History

In July 2006 a 14-year-old male patient was admitted to Ghaem general hospital in Mashhad, Iran with 3 days history of complaining acute right lower extremity pain. He lived in rural area and had no past medical or surgical history. In the first Physical examination, the affected leg observed pallor, cold slightly tender, and without pulses. On further examination, his heart rate was 70 per minute with a blood pressure of 100/60 mmhg. On cardiac auscultation, a low pitched 2/6 systolic murmur was audible at left lower sternal border with no radiation and clear lung fields. His electrocardiogram was normal.

Routine laboratory tests were normal. Femoral angiography demonstrated a filling defect in the right common, internal and external iliac arteries and complete occlusion of external iliac and common femoral arteries with a poor collateral circulation. The patient was prepared for elective explorative vascular surgery. In surgical exploration of the femoral artery was done on 18 July 2006, by open incision showed an unusual filling defect expanding the arterial lumen. Cysts were excised and arterial embolectomy was performed.

After the first surgery, the histopathologic investigation reported Hydatid cysts. Subsequently medication therapy with albendazol at a dose of 10 mg per kg administrated for 10 days and he also underwent further investigation.

Chest radiograph and abdominal Computerized Tomography scanning and ultrasonography were normal. No other visceral localization of the disease was found. Echocardiography revealed a mobile mixed mass lesion of 4.0 x 3.5 cm in dimensions with a 6 mm pedicule (Fig. 1A, 1B), located at the anterior free wall with bulging into the left ventricle. There were no echocardiographic signs of obstruction. An indirect hemagglutination test for *E. granulosus* was positive.

The patient underwent cardiac surgery on 1 august 2006 through a median sternotomy and general anesthesia. Cardiopulmonary bypass using bicaval cannulae and an arterial cannula positioned in the ascending aorta. Blood cardioplegia was used. The

myocardium was opened and the mass was seen in the interventricular septum and it was totally removed.

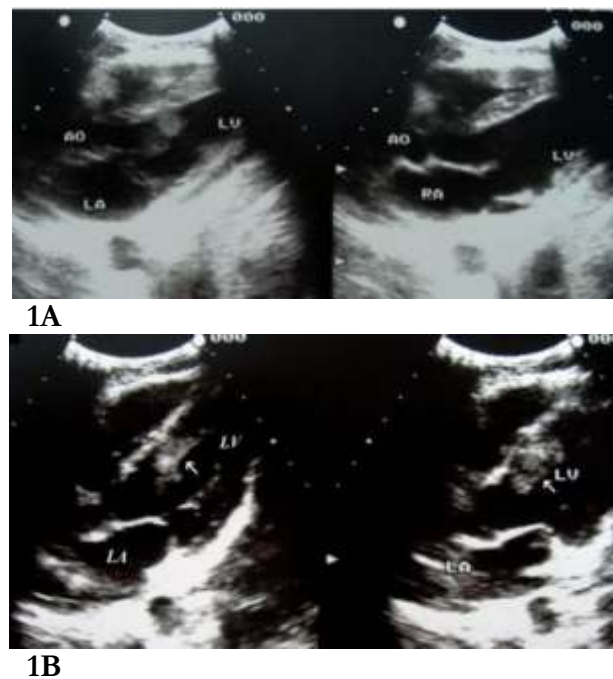
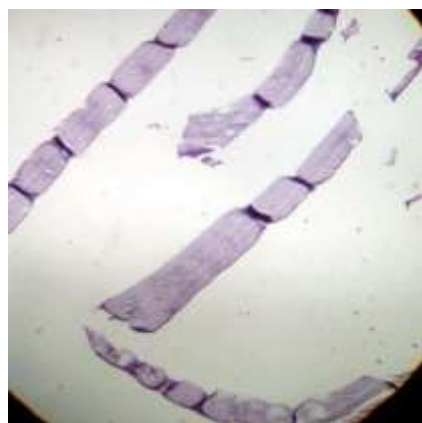

Fig. (1A, 1B): Echocardiography revealed a mobile mixed mass lesion of 4.0 x 3.5 cm in dimensions with a 6 mm pedicule

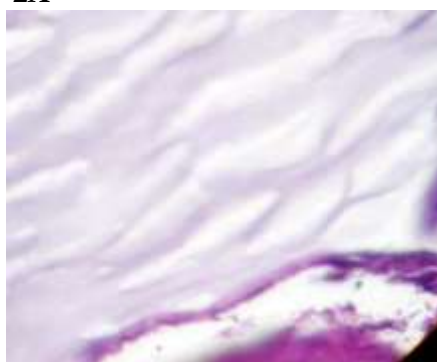
The cavity had no communication with the ventricular cavities. After complete resection, the cavity closed with primer suturing without felt. Postoperative gross and histopathological examination of the excised mass revealed a complicated hydatid cyst confirming complete excision (Fig. 2A, 2B).

The postoperative period was uneventful. The echocardiogram taken after the operation was normal. He was discharged with good condition after 7 days with prescription of a 3-month course of albendazole (200 mg twice daily).

The patient was asymptomatic and the sixth month and one year post-operative echocardiography no further accumulation was found. The follow-up of the patient for 7 years by clinical and serological tests showed no evidence of recurrence.



2A



2B

Fig. (2A, 2B): Post-operative histopathological examination of the excised mass performing a hematoxylin eosin stain

Discussion

Human hydatidosis is typically due to infection with the canine tapeworm *E. granulosus* (4). Hydatid disease is commonly caused by the parasite *E. granulosus*. Dogs and other carnivores are the primary host and sheep the intermediate host, whereas humans are the accidental/intermediate host who do not complete the life-cycle of the parasite. Humans usually become affected by the ingestion of food or milk or water contaminated by dog faeces containing the ova of the parasite (3). When a human ingests the eggs, embryos escape from the eggs, penetrate the intestinal mucosa, and enter the portal circulation. Most are filtered out by the liver or the lungs, but some escape into the general circulation to involve the brain, kidneys, bones, heart, and other tissues (4).

The diagnosis is usually made by combination of clinical findings, Imaging and serological tests. Also a high suspicion and history of exposure in an endemic area gives clue to the diagnosis (3). Cardiac hydatid cysts account for less than 2% of all hydatid diseases. They most commonly affect the left ventricle (55–60%), but also the right ventricle, left atrium (8%), pulmonary artery, pericardium (7–8%) and the interventricular septum (5–9%). The clinical presentation of cardiac hydatid disease is variable and the diagnosis is difficult. Since cystic mass grows slowly, it is usually asymptomatic or can produce atypical or mild symptoms depending on localization; however, rupture of the hydatid cysts may induce embolism or life-threatening anaphylactic shock (5, 7, 8). When the interventricular septum is involved Complications such as anaphylaxis and embolisation into pulmonary and systemic sites can occur (6).

Early diagnosis of this condition is crucial to avoid these complications. In our case the unusual presentation revealed femoral embolisation caused by interventricular septum. Imaging indicated left ventricular septum as a probable primary site for ileofemoral artery location. Surgical treatment is the only option for cardiac hydatid disease since medical therapy does not offer insurance against rupture of the cyst and its potential complications (3). Resection of an intracardiac cyst by open cardiac surgery is recommended to avoid the grave complication of rupture, which is as common as 39 % based on literature (2, 3).

In our case, the hydatid cyst was located in the interventricular septum. The importance of our case rests in the unusual location of the hydatid cysts and also it's unusual presentation. In such cases, differential diagnosis should include cardiac tumors, thrombus, myxoma and other rare intracardiac tumors, such a sarcoma.

Recurrence has been reported in 10% of the patients undergoing hydatid cyst surgery due to spillage of protoscoleces (9, 10). In this case, after 7 years follow-up with clinical and serological tests showed no evidence of recurrence, confirming the successful removal of the cysts.

Conclusion

This case emphasizes that, in endemic countries, primary cardiovascular echinococcosis should be considered in the differential diagnosis and conditions. Particularly when the patient report vascular or cardiac relevant manifestations or symptoms be observed in initial physical examinations.

Conflict of interests

The authors declare that there is no conflict of interests.

References

1. Tuncer E, Tas SG, Mataraci I, Tuncer A, Donmez AA, Aksut M, et al. (2010).Surgical treatment of cardiac hydatid disease in 13 patients. *Tex Heart Inst J*, 37(2):189-93.
2. Yaliniz H, Tokcan A, Salih OK, Ulus T (2006). Surgical treatment of cardiac hydatid disease: A report of 7 cases. *Tex Heart Inst J*, 33(3):333-9.
3. Kamath SM, Mysorekar VV, Rao SG, Varma RG (2009). Intraventricular hydatid cyst in a child. *Indian J Pathol Microbiol*. Oct-Dec, 52(4):571-2.
4. Polat P, Kantarci M, Alper F, Suma S, Koruyucu MB, Okur A (2003). Hydatid disease from head to toe. *Radiographics*, 23(2):475-94.
5. Elangovan S, Harshavardan K, Meenakshi K, Swaminathan TS, Murthy P (2004). Left ventricular hydatid cyst with myocardial infarction in a patient with severe rheumatic mitral stenosis. *Indian Heart J*, 56(6):664-7.
6. Erentug V, Bozbuga N, Kirali K, Mataraci I, Kaymaz C, Balkanay M, et al. (2004). Cardiac hydatid cysts: surgical treatment and results. *J Card Surg*, 19(4):358-60.
7. Wang HB, Li M, Wen H (2010).Isolated cardiac hydatid cyst. *J Card Surg*, 25(6):702-3.
8. Muthu SK, Thiagarajan A, Govindarajan S, Coutinho CM, Gunawardena WJ, Swaminathan TS (2007). Hydatid cyst of the cardiac interventricular septum: report of two cases. *Br J Radiol*, 80(959):e278-82.
9. Ameli M, Mobarhan HA, Nouraii SS (1989). Surgical treatment of hydatid cysts of the heart: report of six cases. *J Thorac Cardiovasc Surg*, 98(5 Pt 2):892-901.
10. Saad RA, Amer KM, Migliore M, Aziz T, Azzu A (2003).Right intraventricular hydatid cyst of the heart. *Asian Cardiovasc Thorac Ann*,11(2):160-2.