



## Unusual Presentation of Interventricular Hydatid Cyst: A Case Report

*\*Hanif TABESH<sup>1,2</sup>, Hossein AHMADI TAFTI<sup>3</sup>, Sara AMERI<sup>2,4</sup>*

1. School of Medicine, Shahid Beheshti University of Medical Sciences, Tebran, Iran

2. Dept. of Clinical Research, Tebran Heart Center, Tebran University of Medical Sciences, Tebran, Iran

3. Dept. of Cardiovascular Surgery, Tebran Heart Center, Tebran University of Medical Sciences, Tebran, Iran

4. School of Medicine, Tebran University of Medical Sciences, Tebran, Iran

**\*Corresponding Author:** Email: hanif.tabesh@gmail.com

(Received 15 Aug 2014; accepted 10 Nov 2014)

### Abstract

*Echinococcus* infection typically affects liver and lungs while rarely occur through heart. Cardiac hydatidosis can be fatal or lead to major complications if it is not treated. The majority of patients with cardiac hydatid cysts complain from cardiac problems as their first presentation. However, this article reports an unusual case suffers from an interventricular hydatid cyst presented by abdominal pain on 2013. After the patient transferred to Tebran Heart Center, surgical cyst excision with removing germinal layer and concurrent albendazole therapy was prescribed for the management of this Iranian 15 year old female.

**Keywords:** Echinococcosis, Heart, Abdominal pain

### Introduction

*Echinococcus* infection is still a major health problem in endemic areas, mostly livestock-raising countries (1). This infection affects liver and lungs more than other organs. 0.5% - 2% of infected patients have heart involvement that commonly have previous hydatid cyst disease, only 4% of cardiac cases experience primarily involvement of interventricular septum (2, 3). Most cases reported heart failure as first presentation (4) however, our case complained from abdominal pain.

### Case Presentation

On December 2013, a 15-year-old female presented to a clinic complained of abdominal pain. Routine blood lab tests were unremarkable. A cystic like lesion on right ovarian revealed on radiologic studies. The cystic lesion was excised dur-

ing laparotomy surgery, which is then reported as follicular cyst by histopathology department.

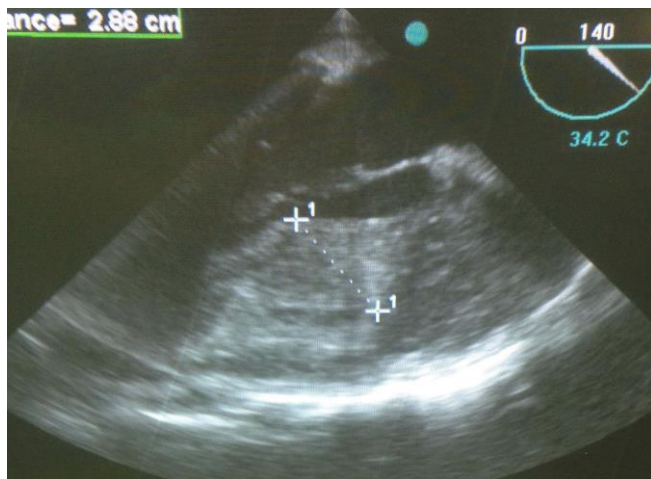
As the patient did not become symptom-free one month after the surgery, an echocardiography was done and revealed hypermobile masses at mid part of interventricular septum. She transferred to our facility (Tebran Heart Center) for more needed work ups.

Electrocardiogram showed Q and inverted T waves on inferior leads and QS pattern through V1 to V6. Another transthoracic echocardiography (TTE) confirmed the presence of a large interamular cystic mass (about 15×9 mm) on mid part of interventricular septum with protrusion to left ventricle (LV) cavity with a mobile fibrin mass on its surface and left ventricular ejection fraction of 55% (Fig.1). Abdominal ultrasonography was inconspicuous. Low-density areas in spleen and

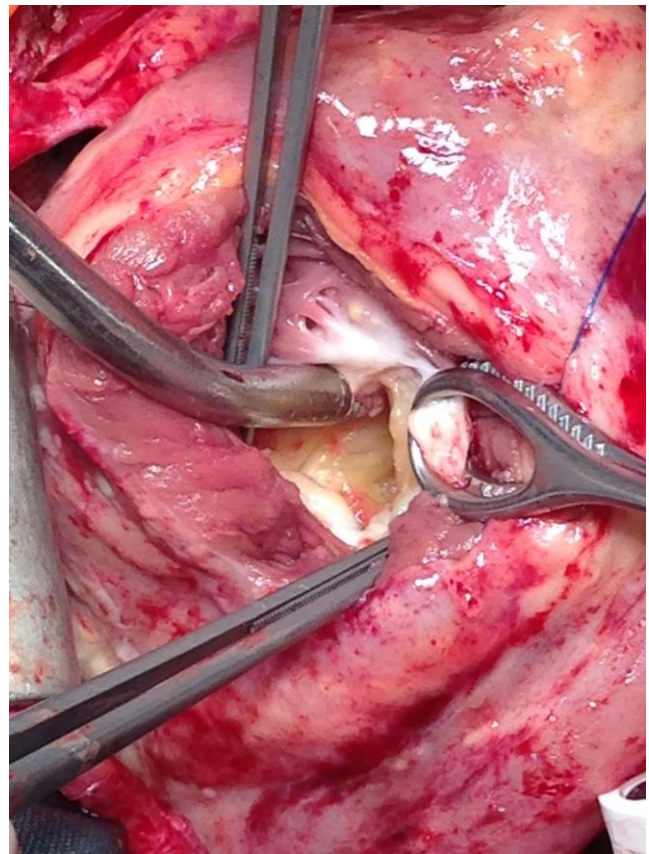
both kidneys compatible with segmented infarctions were described on abdominal computed tomography (CT). An embolic occlusion of superior mesenteric artery revealed on dual source multi slice CT angiography.

The patient underwent a cardiac surgery to excise the interventricular mass. Median sternotomy was performed and cardiopulmonary bypass was established. After cross clamping the aorta, isothermic, potassium-enriched blood cardioplegic solution was consumed for cardiac arrest. The cyst was accessed throughout an incision parallel to and 2 cm on the left side of the left anterior descending coronary artery (LAD) (Fig.2). Whole contents of the cyst were aspirated and immediately sent for histopathologic evaluation. Diagnosis of hydatid cyst was confirmed as we expected. Therefore, we irrigated the cavity with 20% hypertonic saline solution after removing its germinal membrane. The perioperative and postoperative periods were uneventful. The patient was recommended to take 400 mg of albendazole every 12 hours for 12 weeks to diminish the likelihood of infection relapse.

Based on medical Ethics Committee of Tehran University of Medical Sciences, a written informed consent was obtained from the patient for publication of this article and accompanying images.



**Fig.1:** Echocardiography shows interventricular cyst



**Fig.2:** Approaching the interventricular cyst by left side ventriclotomy

## Discussion

However hydatid disease is endemic in some regions like Mediterranean countries, the Middle East, the southern part of South America, Iceland, Australia, New Zealand and China; it should be considered everywhere because of immigration(5). Liver or lungs involved in about 90% of patients with hydatid infection. Muscles, bones, kidneys and spleen can also being involved with much lower probability. In patients with cardiac involvement which is very rare (6, 7), left ventricle cysts accounts for 55%-60% of cases followed by right ventricle (15%), interventricular septum (5%-9%) and right atrial involvement reported in 3%-4% of cases(8). In some cases with multiple organ involvement with hydatid cysts, cardiac hydatidosis is reported (9, 10).

Manifestations of hydatid infection depend on parasite load, site and the size of the cysts however many patients keep on asymptomatic for several years. Symptoms can be as a matter of mass effect (e.g. obstructive jaundice and abdominal pain in liver cysts or pleuritic chest pain and dyspnea in lung involvement) or leakage of the cyst like anaphylactic shock and sepsis. Cardiovascular involvement can present by arrhythmia, angina, valvular dysfunction, pericardial reaction, pulmonary or systemic embolism, pulmonary hypertension, and anaphylactic reactions. Right ventricle cysts are more prone to rupture, compare to cysts sited on left ventricle, which may lead to pulmonary embolization, a lethal complication (11). Cysts located on interventricular septum can lead to obstruction of the right or left ventricular outflow or atrioventricular block and syncopal attacks by compression effects on conduction pathway (12, 13). However, our case presented with abdominal pain, which makes it unique.

Since using serologic tests like indirect hemagglutination test and ELISA with sensitivity of 80% can assist the diagnosis of the hydatid infection, false negative results should be considered. In further evaluations, plain films can just demonstrate a cyst with rim calcification but CT or magnetic resonance imaging (MRI) can demonstrate more details especially about daughter cysts to confirm the diagnosis. Ultrasound is another imaging modality, which can be helpful in diagnosis by showing daughter cysts. In detecting intracardiac echinococcosis, TTE is first choice as it is a noninvasive test with high sensitivity to demonstrate cardiac cysts. CT or MRI will be the next step to corroborate the diagnosis of cardiac hydatidosis and check the extension and anatomic relationships of the cysts (2, 12).

Preferred treatment in cardiac hydatidosis is surgical excision (4). It is recommended to operate the patient when he is on cardiopulmonary bypass, aspirate the entire contents of the cyst, and remove the germinative layer (14), as we did in this case report. Twenty percent hypertonic saline is one of protoscolicidal agents that can be used not only for irrigation of remaining cavity but also for preventing intraoperative local infection dissemi-

nation (4). Medical treatment with albendazole 400mg, twice a day, 4 days preoperatively and for 4-12 weeks after the surgery could be an effective suggestion to diminish the chance of recurrence (12).

## Conclusions

Cardiac hydatidosis can have diverse presentations like heart failure or abdominal pain and it is a rare condition. It can be fatal or lead to major complications without treatment. TTE, CT and MRI can confirm the clinical suspicion. Surgical excision with removing germinal layer and concurrent albendazole therapy showed successful results in treating interventricular hydatid cysts.

## Ethical considerations

Ethical issues (Including plagiarism, Informed Consent, misconduct, data fabrication and/or falsification, double publication and/or submission, redundancy, etc.) have been completely observed by the authors.

## Acknowledgements

The authors declare that there is no conflict of interests.

## References

1. Losanoff JE, Richman BW, Jones JW (2002). Cardiac hydatid cysts. *Ann Thorac Surg*, 73:699-700.
2. Dursun M, Terzibasoglu E, Yilmaz R, Cekrezi B, Olgar S, Nisli K, Tunaci A (2008). Cardiac hydatid disease: CT and MRI findings. *AJR Am J Roentgenol*, 190:226-32.
3. Kaplan M, Demirtas M, Cimen S, Ozler A (2001). Cardiac hydatid cysts with intracavitary expansion. *Ann Thorac Surg*, 71:1587-90.
4. Shehatha J, Alward M, Saxena P, Konstantinov IE (2009). Surgical management of cardiac hydatidosis. *Tex Heart Inst J*, 36:72-3.

5. Torgerson PR (2013). The emergence of echinococcosis in central Asia. *Parasitology*, 140:1667-73.
6. Rostami Nejad M, Hoseinkhan N, Nazemalhosseini E, Cheraghipour K, Abdinia E, Zali M (2007). An Analysis of Hydatid Cyst Surgeries in Patients Referred To Hospitals in Khorram-Abad, Lorestan during 2002-06. *Iran J Parasitol*, 2:29-33.
7. Mohammadzadeh Hajjpirloo H, Bozorgomid A, Alinia T, Hazrati Tappeh K, Mahmodlou R (2013). Human Cystic Echinococcosis in West Azerbaijan, Northwest Iran: A Retrospective Hospital Based Survey from 2000 To 2009. *Iran J Parasitol*, 8:323-326.
8. Tetik O, Yilik L, Emrecaan B, Ozbek C, Gurbuz A (2002). Giant hydatid cyst in the interventricular septum of a pregnant woman. *Tex Heart Inst J*, 29:333-5.
9. Mahmoudi S, Elikae S, Keshavarz H, Pourakbari B, Mamishi S (2012). Pediatric Hydatidosis in Iranian Referral Pediatrics Center. *Iran J Parasitol*, 7:87-91.
10. Sabouni F, Ferdosian F, Mamishi S, Nejat F, Monnajemzadeh M, Rezaei N (2010). Multiple Organ Involvement with Hydatid Cysts. *Iran J Parasitol*, 5:65-70.
11. Leila A, Laroussi L, Abdennadher M, Msaad S, Frikha I, Kammoun S (2011). A cardiac hydatid cyst underlying pulmonary embolism: a case report. *Pan Afr Med J*, 8:12.
12. Maroto LC, Carrascal Y, Lopez MJ, Forteza A, Perez A, Zavanella C (1998). Hydatid cyst of the interventricular septum in a 3.5-year-old child. *Ann Thorac Surg*, 66:2110-1.
13. Eren EE, Aykut S, Kayihan A, Aydogan H, Dagsali S (1989). Echinococcal cyst of the interventricular septum with right ventricular protrusion. *Tex Heart Inst J*, 16:292-5.
14. Tiryakioglu O, Vural H, Ozyazicioglu AF (2009). The curative excision of left ventricular hydatid cyst. *Heart Lung Circ*, 18:57-8.