



Macroscopic Hydatiduria: An Uncommon Pathognomonic Presentation of Renal Hydatid Disease

*Ali HAMIDI MADANI, Ahmad ENSHAEI, *Farshid POURREZA, Samaneh ESMAEILI, Mohammad HAMIDI MADANI*

Urology Research Center, School of Medicine, Guilan University of Medical Sciences, Rasht, Iran

***Corresponding Author:** Email: urc1384@yahoo.com

(Received 11 Dec 2014; accepted 25 Jun 2015)

Abstract

Isolated renal hydatid disease is a rare endemic infestation caused by larval form of *Echinococcus granulosus*. Hydatiduria is an uncommon presentation of renal hydatid disease. In 2012 a 34-year-old female referred to Razi Hospital, Rasht, Iran with complaints of right flank pain and grape-like material in urine. Diagnosis was made by ultrasonography and CT scan. The patient was treated surgically with nephrectomy in combination with perioperative chemotherapy with albendazol.

Keywords: Hydatiduria, Albendazole, Renal hydatid cyst, Iran

Introduction

Hydatid disease is a worldwide zoonosis caused by infection with a small tapeworm parasite called *Echinococcus granulosus*. Sheep and cattle are intermediate hosts for the pastoral form, and humans are an accidental intermediate host (1-2). Patients with hydatidosis usually present with hepatic (liver) (75%), pulmonary (lung) (15%), and other organ involvements (10%) (3-5). Renal hydatid disease is usually seen in tropical countries. Hydatiduria is urinary excretion of microscopic scolexes or macroscopic membranes and/or daughter cysts. It is usually microscopic and just happens in only 10–20% of renal hydatidosis cases (1-6).

Hydatid cyst of the kidney is a very rare and just 1–5% of all hydatid disease in humans involving the kidneys (5). Renal hydatid cysts usually reside asymptomatic for years. Opening of renal hydatid cyst into collecting system may result in acute renal colic and/or hydatiduria. However, most of the hydatiduria cases do not have renal colic (7).

We report a case of isolated renal hydatid disease presenting with right flank pain and a sensation of fullness in the abdomen and hydatiduria secondary to opening of hydatid cysts into renal pelvis and urinary excretion of daughter cysts. Successful treatment was accomplished with total nephrectomy in combination with perioperative chemotherapy with albendazol.

Case report

In 2012 a 34-year-old female referred to Razi Medical Center in Rasht, north of Iran, complaining of a dull right flank pain and a fullness feeling in her abdomen since 9 months ago. She had experienced two episodes of grape-like material excretion in urine. The patient's medical history was unremarkable; however, she was living in a rural area and had been in close contact with animals such as dog and sheep. Physical examinations including flank and abdominal exam were normal.

Laboratory tests revealed normal serum creatinine levels and blood cell count, and no abnormalities on urinalysis. Chest x-ray film was unremarkable. No calcification or urolithiasis was seen in renal lodges in plain radiography. Ultrasonography demonstrated a large size multicystic lesion of 6×4×5cm with mixed echogenicity containing multiple septations in right kidney (Fig. 1).

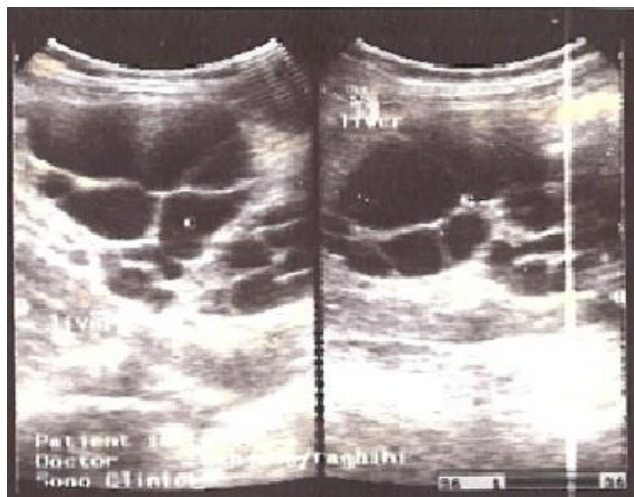


Fig.1: Multiple cysts at sonographic appearance of RT kidney (source: by authors)

Abdominopelvic CT scan showed a lesion containing cystic compartments, originating from middle pole of right kidney, traversing to its pelvis and showing exophytic growth toward perirenal space. Other abdominal organs and structures and contralateral kidney were appearing normal. ELISA serological test and Casoni-Weinberg skin test were negative.

Based on history of passing grape-like material in urine and complex cystic lesion in kidney, and absence of gross involvement in other organs, possible diagnosis of primary renal hydatid disease was made.

The patient was scheduled for surgical exploration. But albendazole treatment was started as a 4-week cycle prior to operation and was continued after it. Because of extensive involvement of kidney and history of hydatiduria, simple right-sided nephrectomy was performed through a subcostal extra-peritoneal flank incision and retroperitoneal cavity was irrigated with hypertonic saline solution. In renal specimen, the collecting system was filled with massive numbers of daughter cysts (Fig. 2, 3).

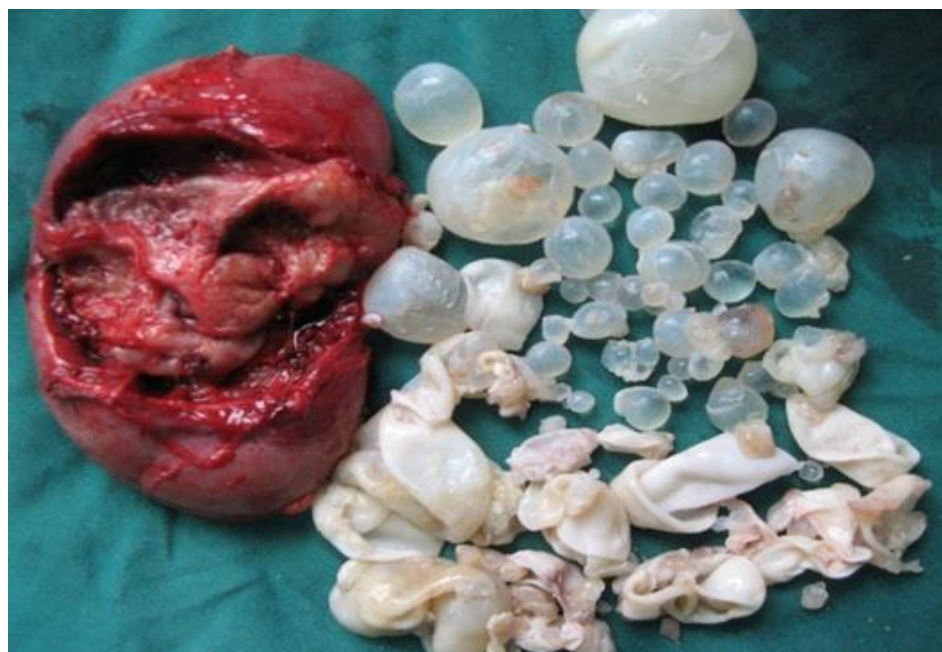

Fig. 2: The excised kidney and multiple daughter cysts (source: by authors)

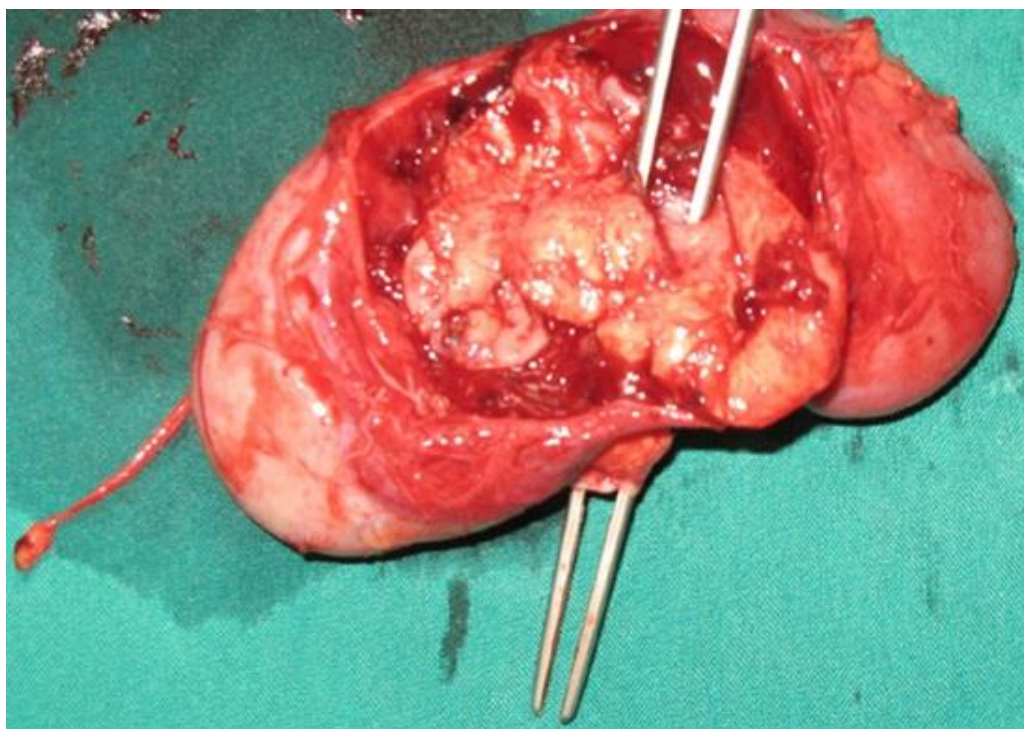


Fig. 3: Communication between cysts and pelvicaliceal system (source: by authors)

The pathologist reported a multilocular hydatid cyst in the nephrectomy specimen. The postoperative period was uneventful, and albendazole 400 mg twice daily was prescribed to prevent metastatic cyst formation for 6 months. We have followed up the patient for 2 year with periodic examination including chest x-ray, retroperitoneal and abdominal cavity and ultra sonography every 3 months, without any relevant problem. The patient was taken informed consent and privacy of information was followed in this study.

Discussion

There are no specific clinical symptoms or signs that will reliably confirm the diagnosis of renal hydatid disease. It can mimic other renal diseases. The combination of clinical history, imaging studies, serological and urine investigations yields a reliable pretreatment diagnosis in only 50% of cases and a presumptive diagnosis in 71% (5). Imaging studies are suggestive but usually inconclusive, and the differential diagnosis between a cyst-

ic renal tumor and complicated cyst may not be made without surgery (5).

The clinical presentation of hydatid disease depends on the size and site of the lesion and the accessibility of the involved organ for clinical examination. Symptoms of renal echinococcosis may be absent since echinococcosis is usually an incidental finding. The most common presentation is chronic flank pain or discomfort from cystic pressure. Hydatiduria, which is the presence of daughter cysts and larvae (hydatid sand) in urine, is easy to recognize macroscopically (grapelike appearance of material). It is the only pathognomonic sign of renal *echinococcosis*, which presents in about 5-18% of cases (3). This event results from the rupture of a cyst into the collecting system (3, 8). Urinary passage of daughter cysts is a rare dramatic presentation (9). There is no specific laboratory finding of renal hydatid disease. Moderate eosinophilia is non-specific, although presents in 20-50% of cases. Different serological tests are being carried out for the diagnosis, screening and post-operative follow up for recurrence. These include the hydatid immunoelectrophoresis, ELISA,

latex agglutination and indirect haemagglutination (IHA) test. The Casoni-Weinberg test as a skin test has little efficacy and has been abandoned nowadays (10).

Renal hydatid cyst can be diagnosed by US, CT and MRI. Ring-like calcification of the cyst can be visualized by plain radiography in 1/3 of patients (11) which may suggest diagnosis of hydatid disease (12).

Excretory urography may reveal collecting system distortion. If hydatid cysts open to the collecting system irregular filling defects can be seen due to daughter cysts. In addition, sometimes the cyst may fill with contrast material. The US and CT features of renal hydatid cysts are similar to those of cysts in other locations. However, CT is superior to US in diagnosis of renal hydatid cyst (13).

Under real time US on changing the patient's posture, there will be shifting of hydatid sand, which may give rise to the "falling snowflake pattern" (4,14). CT may show a single cyst with multiple daughter cysts, or a multiseptated cystic mass with or without calcifications. CT densities of the daughter cysts are significantly lower than the mother cyst (14). In cases of communicating cyst with the collecting system, contrast may enter into the cyst, which may be seen as streaky hyperdense areas in the cyst.

The treatment of hydatid disease is principally surgical. Because of the lack of an absolutely effective systemic scolicidal agent, surgical treatment offers the only hope of cure. In general, surgery is the preferred type of treatment in renal hydatid cysts (4). However, there are also some cases in literature that have healed by only medical treatment with albendazole (12).

Renal sparing surgery is usually applied in most of cases. The cysts should be removed without rupture to reduce the chance of seeding and recurrence. If most of the kidney is invaded by hydatid cyst, then nephrectomy is inevitable (11). Besides, nephrectomy is the preferred type of surgery in cases with hydatiduria.

When medical treatment has been considered, albendazole which is a benzimidazole anthelmintic, believed to be superior to mebendazole for treating hydatid disease. The usual dose is 10-15

mg/kg body weight daily or 400 mg twice daily. For adults, the drug is given in cycles such as twice daily for 28 days followed by a 1-2 week drug-free interval, followed by another course of the drug. For most patients three cycles is sufficient, although the course can be repeated up to 12 times (15).

Postoperative recurrence of intra-abdominal echinococcosis can be seen because of intra-operative rupture of cysts and intraperitoneal spillage. Therefore pre-surgical chemotherapy of infection can reduce the size and number of viable protozoa and therefore postoperative recurrence (16).

Acknowledgements

The authors declare that there is no conflict of interests.

References

1. Mongha R, Narayan S, Kundu AK (2008). Primary hydatid cyst of kidney and ureter with gross hydatiduria: A case report and evaluation of radiological features. *Indian J Urol*, 24(1): 116-7.
2. Parashari UC, Upadhyay D, Khanduri S, Qayyum FA, Bhadury S (2011). Primary renal hydatidosis with associated macroscopic hydatiduria - a computed tomography urography diagnosis with pathological confirmation. *Trop Doct*, 41(3): 187-9.
3. Kilciler M, Bedir S, Erdemir F, Coban H, Sahan B, Ozgok Y (2006). Isolated unilocular renal hydatid cyst: a rare diagnostic difficulty with simple cyst. *Urol Int*, 77(4): 371-4.
4. Choi H, Park JY, Kim JH, Moon du G, Lee JG, Bae JH (2014). Primary renal hydatid cyst: misinterpretation as a renal malignancy. *Korean J Parasitol*, 52(3):295-8.
5. Rextiati M, Mutalifu A, Azhati B, Wang W, Yang H, Sheyhedin I, Wang Y (2014). Diagnosis and surgical treatment of renal hydatid disease: a retrospective analysis of 30 cases. *PLoS One*, 5;9(5):e96602.
6. Gharde P, Wagh D, Patil A (2012). Left renal hydatid cyst presenting as hematuria and macro-

- scopic hydatiduria since last ten years. *Trop Parasitol*, 2(1): 58-60.
7. Unsal A, Cimentepe E, Dilmen A, Yenidunya S, Saglam R (2001). An unusual cause of renal colic: hydatiduria. *Int J Urol*, 8(6): 319-21.
 8. Göğüs O, Bedük Y, Topukcu Z (1991). Renal hydatid disease. *Br J Urol*, 68(5): 466-9.
 9. Loiwal V, Gupta P (2000). Hydatiduria. *Indian Pediatr*, 37(1): 111-2.
 10. Sountoulides P, Zachos I, Efremidis S, Pantazakos A, Podimatas T (2006). Nephrectomy for benign disease? A case of isolated renal echinococcosis. *Int J Urol*, 13(2): 174-6.
 11. Zmerli S, Ayed M, Horchani A, Chami I, El Ouakdi M, Ben Slama MR (2001). Hydatid cyst of the kidney: diagnosis and treatment. *World J Surg*, 25(1): 68-74.
 12. Odev K, Kilinc M, Arslan A, Aygün E, et al (1996). Renal hydatid cysts and the evaluation of their radiologic images. *Eur Urol*, 30(1): 40-9.
 13. Ozbey I, Aksoy Y, Bicgi O, Polat O (2001). Hydatid disease of the urinary tract: review of the management of 9 cases. *Int Urol Nephrol*, 33(2): 329-34.
 14. Rajamagesh, Swaminathan A, Jeyaraman VS, Sivakkolunthu MK (2000). Ruptured renal hydatid cyst. *Ind J Radiol Imag*, 10(1): 47-8.
 15. Von Sinner WN, Hellström M, Kagevi I, Norlen BJ (1993). Hydatid disease of the urinary tract. *J Urol*, 149(3): 577-80.
 16. Miron D, Kawar B, Lumelsky D, Spiegel R, Horovitz Y (2005). Encysted peritoneal hydatidosis in a child-the effectiveness of preoperative therapy with a combination of praziquantel and albendazole. *Ann Trop Med Parasitol*, 99(6): 577-82.