



# Tracking of Infectious Diseases and Deadly Injuries through Signs Observed in Excavated Human Skeletons of 2000 BC/ Iron Age in Iran

*\*Dariush D. Farhud<sup>1,2,3</sup>, Mahsa Azari<sup>2,3,4</sup>, Mehdi Rahbar<sup>5</sup>*

1. School of Public Health, Tehran University of Medical Sciences, Tehran, Iran

2. Research Center for Paleogenomics, Tehran University of Medical Sciences, Tehran, Iran

3. Dr. Farhud Genetics Clinic, Tehran, Iran

4. Department of Archeology, Faculty of Literature and Humanities, Tehran University, Tehran, Iran

5. Organization of Cultural Heritage, Handicrafts and Tourism, Tehran, Iran

**\*Corresponding Author:** Email: [farhud@sina.tums.ac.ir](mailto:farhud@sina.tums.ac.ir)

(Received 10 Jul 2023; accepted 19 Sep 2023)

## Abstract

**Background:** Throughout history, many wars have occurred for various reasons, and many empires and kings have fallen or many people killed by wars. Wars were not always due to the conquest of the country. In the Iron Age, societies were governed by tribes at the head of the tribe, and war was only for to seize property, slaves, and food. Our research area is the same period as the Medes Kingdom, which included the union of small, large tribes, wars between tribes existed in that period, and their signs can be seen on the remains of the people of that period.

**Methods:** Our research is related to human remains from Sagezabad cemetery, Qazvin plain, which dates back to 2000 BC (Iron Age 2 and 3) in Iran.

**Results:** The blows on the remains were very serious and caused death. We have discussed how to kill by “considering the injured body”.

**Conclusion:** Our investigation of how people were killed in war based on injury marks and bullet holes in bones, and simulating those injuries to body tissues and organs also, people who had bone cuts from the war and survived and had bone repair and died due to lack of nutrients and infection were also discussed.

**Keywords:** Ancient war; Paleopathology; Ancient skeletons; Infectious disease; Iron Age; Iran

## Introduction

The war between ancient and special people of cemetery Sagezabad has been more between tribes so their goal was of the tools used in this type of hand-to-hand warfare including arrows, maces, swords or daggers. The region of Qazvin plain 4000 years ago is the same as the ancient

cemetery of Iron Age 2 and 3, related to the period of the Mede's rule. The Medes government was attacked by Assyria and Urartu from the west and northwest of Iran. Therefore, the living needs of the people of the west were in short supply and danger every moment by these tribes



Copyright © 2024 Farhud et al. Published by Tehran University of Medical Sciences.

This work is licensed under a Creative Commons Attribution-NonCommercial 4.0 International license.

(<https://creativecommons.org/licenses/by-nc/4.0/>). Non-commercial uses of the work are permitted, provided the original work is properly cited

(1). They attack the near tribes from the west to compensate for the lack and daily needs of their tribe, of course, another reason could be climate change, famine and migration of newly arrived tribes. However, this cemetery contains 5 consecutive layers of burials with the Meds culture based on burial gifts and dated 850-1050 BC (2) based on radiocarbon and includes Iron Age 2 and 3 of Iran. In layer 5, the lowest layer, only the remains of horses were found, and in layer 4 (the layer above 5): the burial of the dead of the war with fatal injuries was buried along with funeral gifts and war tools, which means that it is likely that during this period the society was still established and the customs and rituals were still in place and according to the first period of burial, that is, a new tribe that by another tribe has been attacked and in the higher layers, in the same higher layers of the same culture but the signs of the reduction of gifts and in some burials the absence of gifts and remains with severe infectious diseases can be seen. The time distance between the layers from the 4<sup>th</sup> probability near 5-10 years apart (Based on archaeological evidence (3)).

Addressing how people have been killed throughout history is an exciting topic for simulating historical moments, for those killed in the war of Athens (4) and how they died, such as mutilation, has been discussed by researchers (5). In addition to these types of topics, the expression of events during the war (6) and how they affect the morale of other people or other warriors are also among the topics of interest to historical researchers; But to form an idea of how they died, the stages must be examined with knowledge (7). For example, in the first step of the anatomy of the human body, types of arteries (8), congenital abnormalities of arteries (9), cause of obstruction (10), the diameter of the arteries (11), and also, we should have full knowledge of the essential tissues of the body, which if damaged will cause death immediately, such as the lungs and the main arteries of the heart as the source and center for pumping blood.

In addition, one should pay attention to the structure of the parts of the body that were the most damaged based on ancient weapons and the

impact on those parts was very common in war. Like the lung (12), which is the part where breathing is disturbed in case of bleeding and deep injury and the penetration of blood in the channels (13), as well as damage to the esophagus and trachea or the channels related to the heart (14,15), caused the death of the ancient person in a moment and very early; for the cemetery we are considering in this article, expected to have congenital diseases, the possibility of disruption in the stiffness of the arteries (16) and in sufficiency such as heart failure or septal blockage of the heart (17) or vision, brain(18), blood pressure and vital organ failure (19) have also existed which contributed to the death of the ancient person. In this cemetery, there are many signs of injuries and blows from heavy objects and fractures on the skull, which cause brain hemorrhages and obstruction of important holes, craniotomy and becomes inflamed.

Bleeding in the brain is something that causes brain death and serious disorders (if person survives) in a person's life. If the ancient people had diseases before the war, they are less able to recover due to the injury of the body parts, or the previous disease caused pressure and early death of the person (20).

In the following, with the knowledge of anatomy (skeleton, tissue, artery, nerve), we have tried how body organs are damaged and people are killed during war and death due to another cause has been treated with infection due to the existence of famine after the war.

## Materials and Methods

To investigate the topic of the article, we have studied the human bone remains of Iron Age 2 and 3 Sagezabad (21) cemetery with an age of nearly 4 thousand years in the Qazvin plain of Iran. Some of the bone remains were excavated by the archaeologist author of the article in the 2019 excavation. According to the signs of damage or the presence of arrows inside the body of the bones, we collect information related to the anatomy of bones, tissues, arteries, nervous sys-

tem (22,23) and understanding the function of each one, we realized how bleeding and injury of each part can cause death; in order to find out the gender from the bones, it is necessary to learn before exploring and using the atlas (24,25).

### ***Ethics approval***

The relevant license was obtained from the Institute of Archeology of Tehran University with number 713/1798.

## **Results**

### ***The first part***

Fig. 1: The burial relating to a mature female is the aristocrat that is buried along with food and gifts. Two oxidized iron rings can be seen around the ulna and radius bone on her right side. Undoubtedly, she had an aristocratic ceremony and burial; she is a nobleman who was killed during the war and the fact that she was buried with jewelry and gifts indicates that she was buried by her family and those around her buried her with great respect and ceremonies.

Given her calcified skull bone, the sign of a healed parietal trauma and the presence of signs of oral infection, it is possible that her body had an infection during her lifetime; also, there are signs of adhesion and crookedness in the vertebrae of the cervical spine and thoracic and protrusion of the edges of the lumbar vertebrae and a lot of calcifications in the sacrum and ilium; it is possible that she had tuberculosis because the general symptoms are similar to this type of infection.

(Being a noble in this woman's period does not mean being a princess. This female has been living in a small community with other villagers or people beginning of urbanization), with lack of hygiene in the past. According to her age, she is likely to be a middle-aged adult (based on sutures, tooth wear, growth charts; there is a possibility that due to the prevalence of this type of disease in the community, it was also transmit-

ted to her by her servants. but the reason for her death was that she was hit by 3 arrows from the front and the depth of the injury was so great that her relatives could not remove the arrows from her body and then bury her pay attention to the model to make the extent of damage, should be clarified according to the tissues and the possibility of bleeding areas. The red arrows show the arrows and their location in the woman's body. Arrow number 1, it is possible that this woman had extensive muscle tissue in the hit area because half of the arrow passed through the body tissue without any bone damage or hitting the rib bone and manubrium which it caused the cut of the esophagus, trachea and the tube related to oxygen, it is also possible that it cut the arteries around vertebra number, corresponding to the thoracic vertebra, the arrow passed through the area above the clavicle and finally, it stops in the humerus area (or the opposite way). Unfortunately, the arrow was not in its original place due to the erosion of the arrow. Arrow number 2, from this shot, the arrow hit from the front, broke the first rib and clavicle, and went near the skull. That is, it has caused injury to the tissue above her heart and shoulder. Most likely, the reason for her burial is the location of the arrows in the woman's body, because the relatives had no other choice considering the existence of such arrows. In this nearly 4000 years old burial, it was very difficult to trace the place where the arrow passed due to the decay of the arrow. Arrow number 3, according to the tip of the arrow that stopped in the disk, the arrows were hit from the front. Arrow number 3 may have cut the aorta and artery and completely disabled the heart. This arrow entered from the middle of the body. It was not entered from left to right or vice versa like arrow number 1, the height of the arrow from the front of the person is very high, it increases the probability that the arrow is from the front and is stopped in the disc of the 12-14 vertebra. This shot ended her life (Fig. 1. A, B, C).





**Fig. 1: A)** burial of an adult female 2000 BC with many gifts including food and jewelry. There are signs of infection in her pelvis and other bones (Original)

In the simulation, the amount of penetration of the arrow to which parts of the body is determined. The path of cutting the tissues, artery, nervous system and bone damage shows the cause of her death due to the damage of which parts. She was shot three times (simultaneously) by three strangers or in another

possibility, according to the area of the arrows, it is possible that she was riding on a cot so first arrow from below and the 2<sup>nd</sup> and 3<sup>rd</sup> arrows from the front. The 3<sup>rd</sup> arrow is the most deadly and the cause of her immediate death. Most likely, based on the evidence, the arrows hit the person according to the numbers.



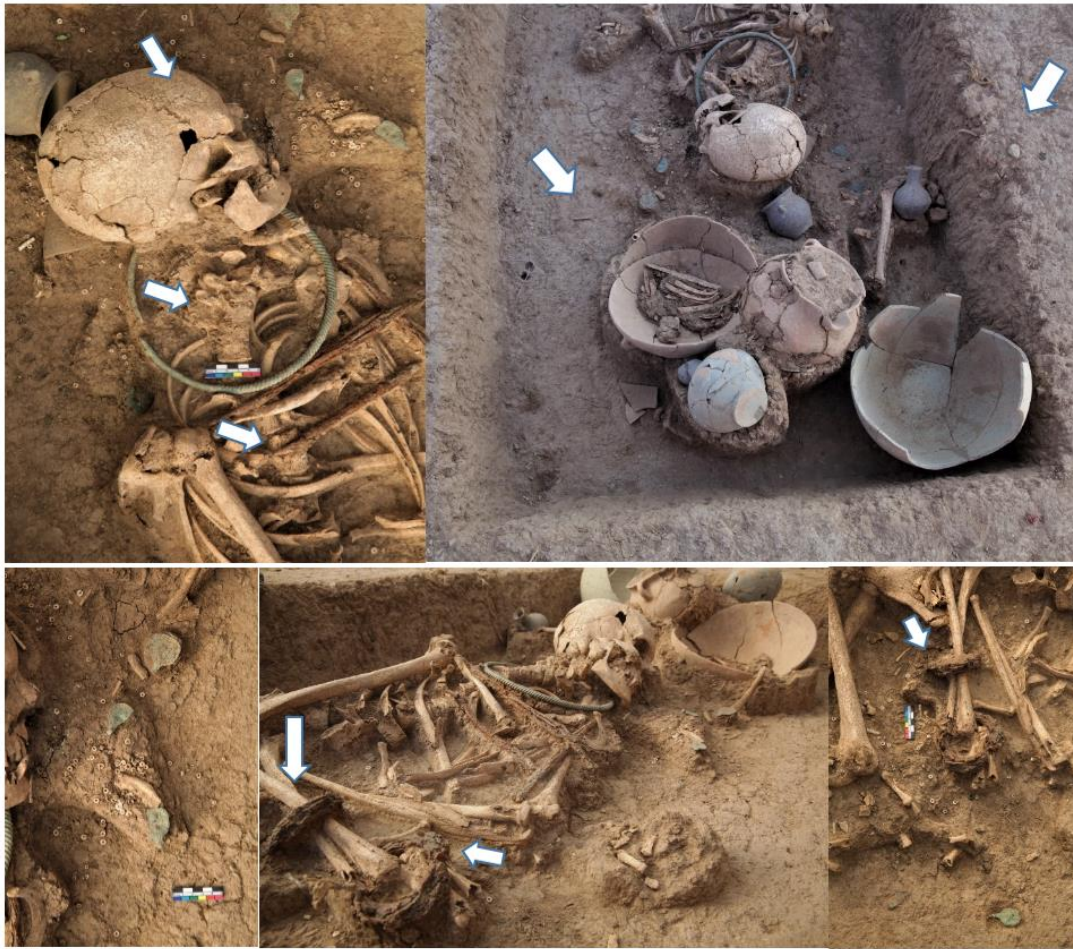

Fig. 1: B) Burial of the killed adult female (original)

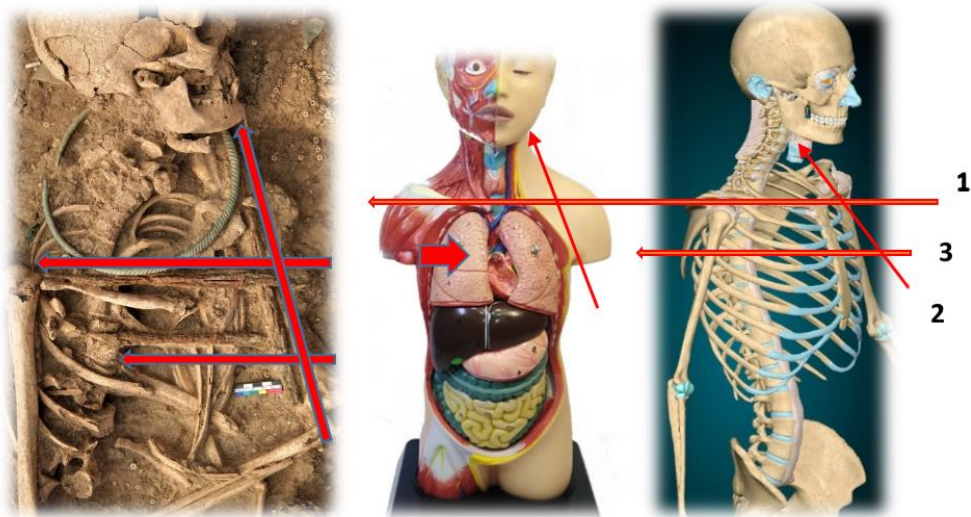


Fig. 1: C) Burial of the killed adult female along with the simulation model of the damage (original)

Fig. 2 is related to an adult male. According to the tip of the arrows, it was an arrow from the back of the head. It is in the area of the thoracic vertebrae and the humerus bone is under the arrow, it is possible that the arrow entered from behind the head and from the center of the body because it is between two humerus. He has dam-

aged the area near the heart or heart artery or the lungs and tubes related to oxygen. This burial is very chaotic, because natural events such as earthquakes or floods cause the movement of ancient remains. Ancient ornaments cause another disturbance in the arrow track.

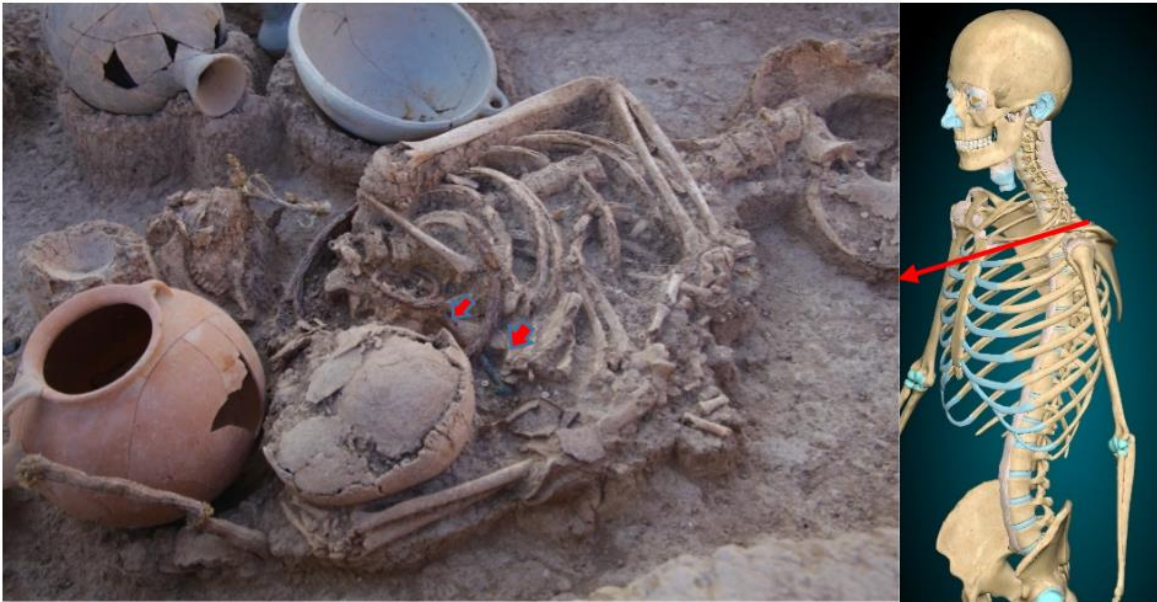

Fig. 2: Burial of the killed adult male with the damage model (original)

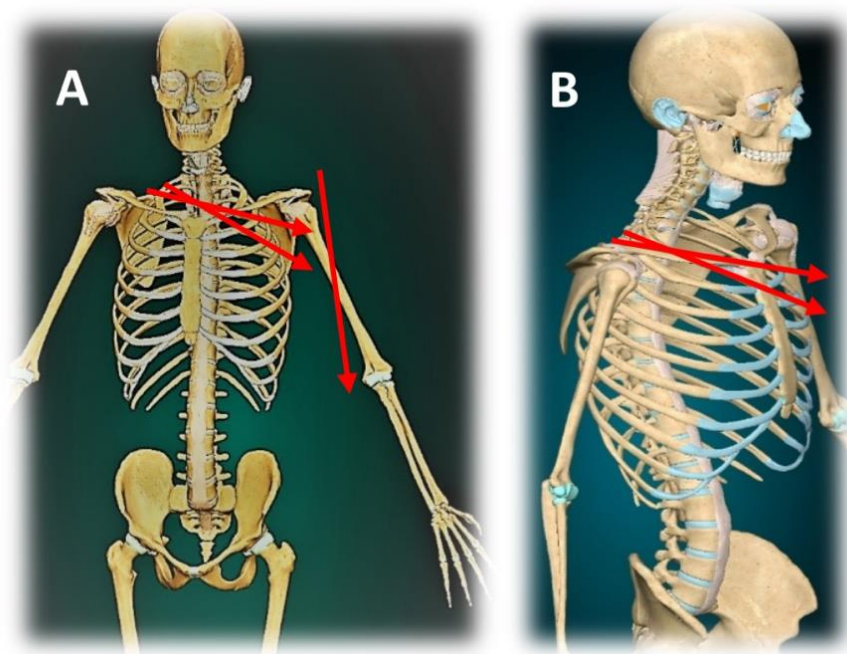
Fig. 3. A is related to the burial of an adult male, according to his arrowhead, he was hit by 3 arrows from the back of the head. Arrow number 1 probably hit the tissues and muscles of his shoulder and hand, maybe it was the first arrow, and the killer, after seeing the unfavorable result, fired again two more arrows to kill him. Arrow number 2 passed through and by damages the sternal end to impression for costoclavicular ligament and by piercing the lung and maybe the artery and breathing tube, the oxygen was disturbed and he had trouble breathing. This arrow is drawn from left to right. Arrows number 3 is likely to be his death and final arrow because this arrow passed through the 1<sup>st</sup> rib and completely split his

throat and it was impossible for him to breathe at this stage based on the evidence. The main arteries were torn and there was severe bleeding. Arrow 2 and 3 came out from above the manubrium, so his death was not caused by damage to the tissue of the heart itself. B, the burial is of an adult female, which is a very chaotic burial, it is very difficult to trace the bullet, but what was clear was that she was hit by more than one bullet, and the bullets hit her in the back of the head. The area between the first and half of the humerus may be an area that includes the arteries and lungs, which means that blood loss or lack of breathing and therefore the damage in these parts caused his death.





**Fig. 3: A)** Burial of an adult male killed by multiple arrows (Original). **B)** The chaotic burial of an adult female (Original)



**Fig. 4: A, B.** The simulation model of the damage for human A and human B (original)

Fig. 4: The skull belongs to an adult male who was seriously injured by a war tool such as a mallet from the right supra-orbital region. From the

right parietal to the occipital region, the bones are broken. There is a possibility of blindness in the right eye. The place where the enemy's sledge-

hammer hit, not found in the burials (it is possible that the enemy's tribe had one of them), had a very devastating effect on the parietal part and the cause of his death, because the bones were broken and crushed and entered the brain tissue, causing severe cerebral hemorrhage and brain

death. The impact was accompanied by a lot of force, which alone causes blood inflammation in the brain and eventually causes bleeding and perhaps cerebral edema and death for the ancient person.

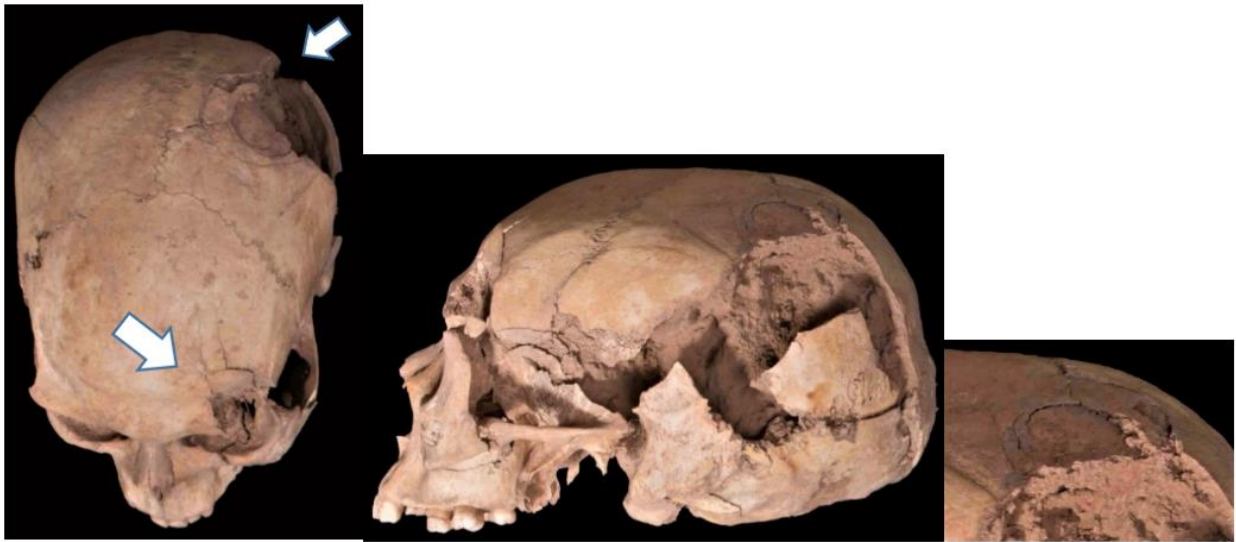

Fig. 4: Hit with two-hammered (Original).

Fig. 5. **A**, a child's skull is cut from the parietal region with a sharp object such as a dagger or a sword. The thinness of the skull bone causes the dagger to enter the brain tissue and cause brain bleeding and death. **B**. Similar to the child's incident, it happened to the adult man's skull near the temporal area and caused the person's death.

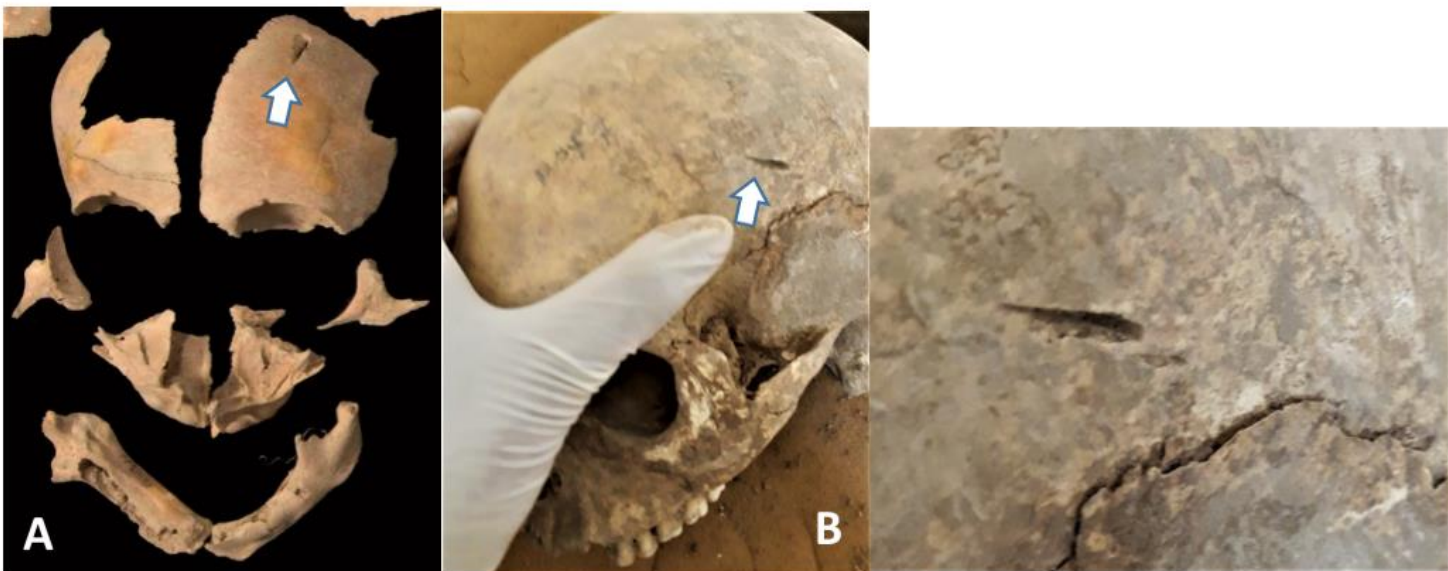
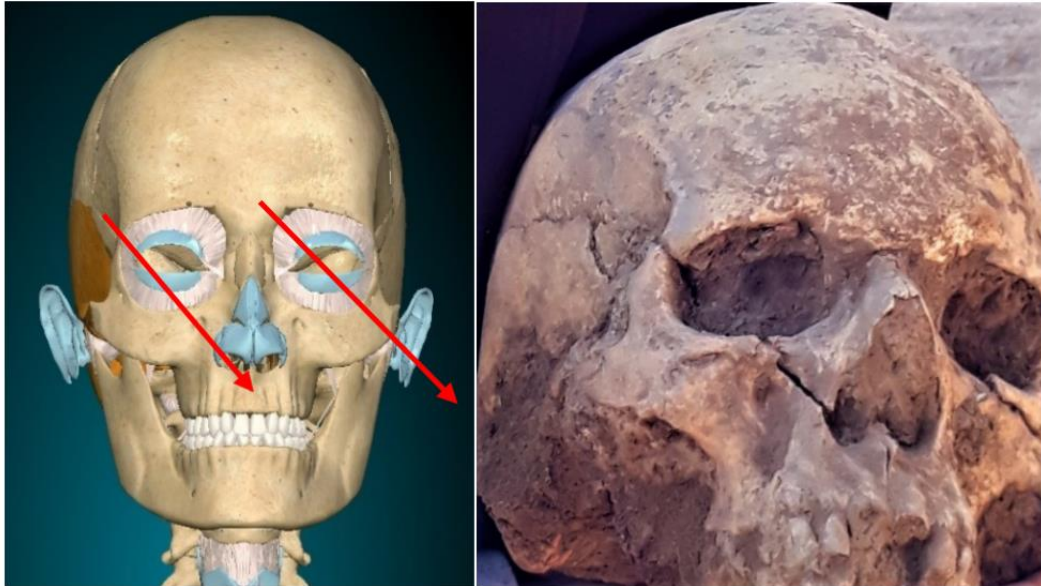


Fig. 5: The skull of a child and an adult man, cut with the tip of a dagger or sword (Original)



Fig. 6: The skull belongs to an adult male who was deeply cut by a sword or dagger from the left side of the area between the supra-orbital and frontal process to the nasal bone and near the maxilla. This cut is extended from the right side

from the nasal to the zygomatic arch. Maybe the injury to the brain and the cutting of the facial bones and damage to the temporal tissue of the brain caused his death.



**Fig. 6:** Two bone cuts with a sword on the skull of an adult male (Original)

Fig. 7: In the layer related to war dead (layer 4), war tools including: dagger or short sword, iron arrowhead (Iron Age 2 and 3), were found among the bones and burials. In this Fig, a num-

ber of war tools embedded (within the tissue area) of the bones of the dead bodies can be seen.



**Fig. 7:** A number of war tools in the burial (Original)

Fig. 8, Cut marks on the pelvis of 2 adult females (A, B) in the area between the ilium and the ischium and near the greater sciatic notch, which shows that a sharp object like a dagger or a sword was sunk in their abdomen and pelvis. That the tip of the sharp object also hit the bone and caused a deep cut in the bone due to the force of the killer. Women may have ruptured in the in-

testines, spleen, and uterus. the spleen helps the body fight infection and cleans old blood cells from the blood stream rupture of the spleen can cause bleeding and threats in the abdomen, and lack of treatment and recovery leads to infection and death. People are likely to be killed after a few hours or days (Fig. 8. A, B).

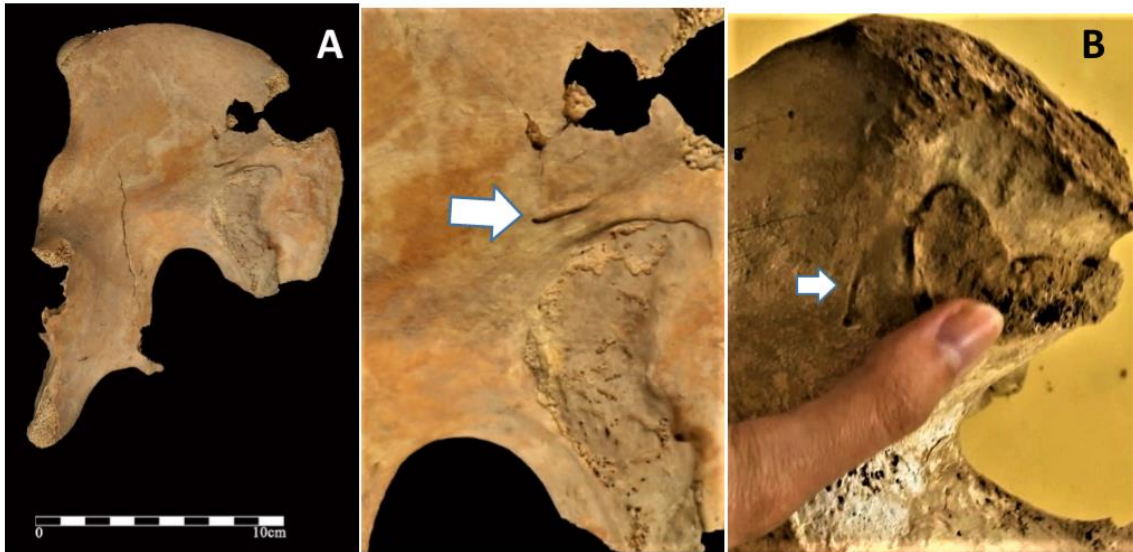


Fig. 8: A, B. Bone cut from the tip of the sword in the pelvis of two adult female (Original)

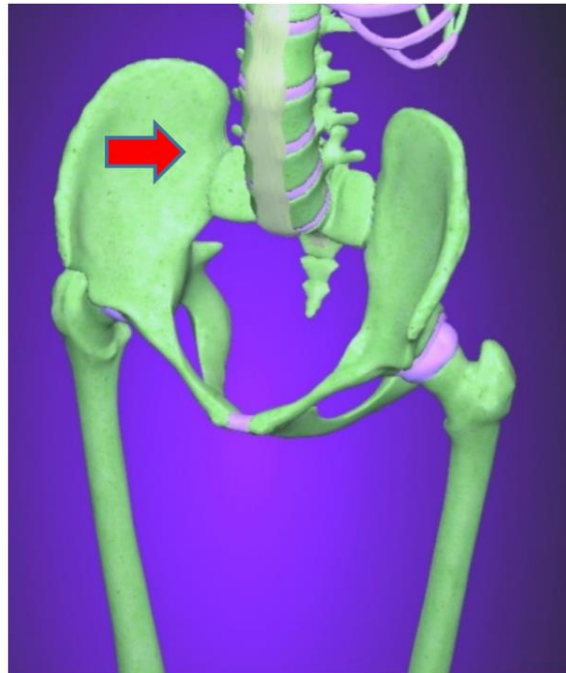


Fig. 8. C):The simulation model of the damage for female A & B (original)



### The second part

Fig. 9. A: the skull belongs to adult male, after layer 4, related to the layer of war; the higher layer (layer 3) includes war wounded and infectious patients due to shortages that occurred after the accident. The layers of the cemetery are 5-10 years apart; these people were injured from the war period but survived. Overtime, their wounds were healed because the wounds were

superficial and not deep and did not enter the brain tissue. The scratch of the sharp object did not apply much force to the brain, but only caused a superficial scratch because the enemy was not hurt vertically and by the tip of the sword or dagger. Perhaps the survivors were revenge fighters or victorious who only scratched the surface.

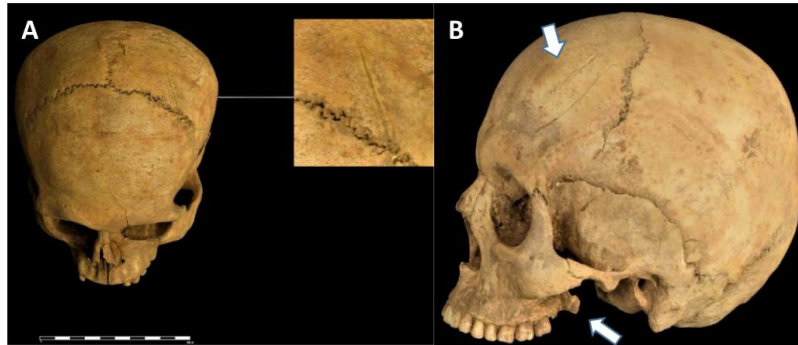


Fig. 9: A, B. Signs of repair of damaged skull bone after injury (Original)

The adult male skull on the right also has signs of infection in the maxilla and it has a healing sign of a few scratches on the parietal. There is severe calcification in the part of the frontal bone, glabella, zygomatic to the maxilla. There is dental hypoplasia because similar signs are seen on the teeth. There are two cavities in the maxilla, possibly related to abscesses and in the 3<sup>rd</sup> molar bone and the end of the

right maxilla, calcite and bone loss can be seen too, the jaw is forward. The possibility of infection in him is high; the penetration of the infection is through a scratch and the reduction of the body's immunity level and the lack of nutrients and the lack of public health after the wound, one of the reasons for infections and more penetration (Fig. 9. B).

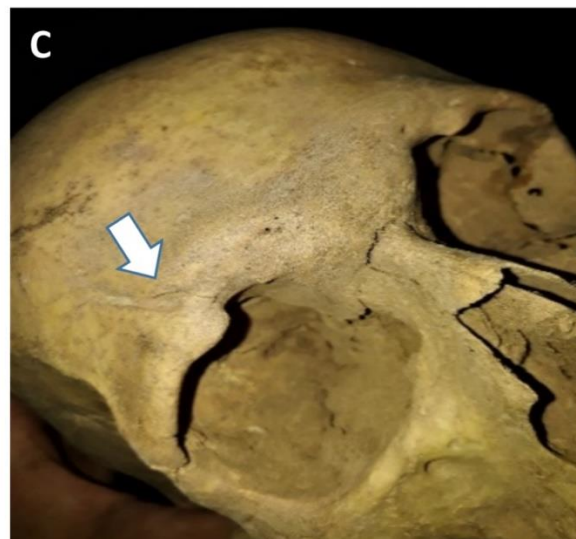


Fig. 9: C. A sign of recovery and bone repair of sharp object entered in the bone of the supra orbital notch (foramen) adult male (Original)

In the figure above, the skull is associated with an adult male. Has wound maybe deep bone cut, restored during his lifetime. It is likely that he has been blind due to the cut that continues to the eye tissue. Bone swelling from the glabella region to the supra orbital notch of the left eye is very clear that it is likely to be due to infection (Fig. 9.C).

Figure 10: The adult skull, which was discovered from the layer above the battle layer, had damage to the zygomatic bone, repaired during his/ her life time (Repair here means changing the damaged bone in the direction of healing).



Fig. 10: Signs of repair of damaged zygomatic bone after wound (Original)

## Discussion

The cause of death has been one of the most interesting and challenging topics throughout history. War and scratches from sharp tools or the existence of an arrow make the work of the explorer easier because the cause of death has a very clear sign, but it is important to examine which tissue is damaged. Which part of a person's body was damaged and how did that injury had been cause an ancient person's death? Correctly understanding the cause of death; it goes without saying; diseases can also decrease the stability patient be of the injured person and act as an additional cause (26,27). Therefore, may be a blow or a scratch is not the only reason for a person to be killed, and other reasons are included. If the beam or sword collides to the limb and vital limb and cause severe bleeding, the person's death and if a tissue such as liver and kidney is hit, the poison enters the blood, which is the

cause of death. It should be kept in mind that if a person's blood coagulation system has a problem due to diseases or lack of nutrients or genetics, infection can enter the body because platelets are limited (28). If a person has anemia and thalassemia, which is very likely due to intra-tribal marriage in this area, the injury can still cause death. We are testing genetics from this cemetery, without a doubt we can reach a 100% answer after the test.

## Conclusion

Injury and tear in some organs of the body causes blood to flow out of the body at a high speed, which this situation is very dangerous for the injured person, because the organs of the protective and restorative department cannot function to improve and as a result, the body will not



reach the necessary substances and oxygen to the cells at a high speed so the organs, one after the other, lose their connection forever and become inactive, finally the person dies. In the article, we tried to find out the cause of death by finding out, which parts of the body were seriously injured. We predicted how long they survived after being wounded. We investigated what caused their death if their injuries were repairable. A wounded person needs care, nutrients and hygiene, if there is a shortage of any of the items in the society, the person's body will be infected and die due to the severity of the infection. The people of Sagezabad suffered from a lack of nutrients and famine after the war, which created a chaotic situation in the society. Therefore, the lack of hygiene and medicine after wounds in the society had caused infection in people.

### Journalism Ethical considerations

Ethical issues (Including plagiarism, informed consent, misconduct, data fabrication and/ or falsification, double publication and/ or submission, redundancy, etc.) have been completely observed by the authors.

### Acknowledgments

The authors gratefully acknowledge the financial support for this work that was provided by Dr. Farhud Scientific Foundation.

### Conflict of interest

The authors declare that there is no conflict of interest.

### References

- Schmandt Besseral D (1981). From tokens to tablets: A Re-evaluation of the so-called numerical tables, *Visible Language*, 15(4):321-344.
- Dehpahlavan M, Jahed M (2021). Evidences of the counting game in iron age 2 and 3in Qara tepe segzabad cemetery. *Parseh Journal of Archaeological Studies*, 5(15):115-134.
- Drewett P (1999). *Field archaeology: An introduction*. UCL Press, pp.: 20-160.
- Rees O (2018). Picking over the bones: the practicalities of processing the Athenian war dead. *Journal of Ancient History*, 6(2): 167-184.
- Tritle L A (2017). *Hector's body: mutilation of the dead in ancient Greece and Vietnam*. The amies of classical Greece, pp.: 335-348.
- Makins M W (2016). Memories of (Ancient Roman) war in Tolkien's dead marshes. *Thersites*, 95(7):89-92.
- Turner S (2015). *Sight and death: seeing the dead through ancient eyes*. sight and the ancient senses, pp.: 157-174.
- Manchot C (1986). *The cutaneous arteries of the human body*. *Plast Reconstr Surg*, 77 (3): 49-76.
- Poynter C W M, Hicks J D (1922). *Congenital abnormalities of the arteries and veins of the human body with bibliography*. General books LLC, pp.: 43-80.
- Heichinger R, Pretterkieber M L, Hammer N, Pretterkieber B (2023). The corona mortis is similar in size to the regular obturator artery, but is highly variable at the level of origin: an anatomical study. *Anat Sci Int*, 98 (1): 43-53.
- Wahood W, Ghozy S, Al- Abdulghani A, Kallmes D F (2022). Radial artery diameter: a comprehensive systematic review of anatomy. *J Neurointerv Surg*, 14(12): 1274-1278.
- Huang W, Yen R T (1998). Zero-stress states of human pulmonary arteries and veins. *J Appl Physiol*, 85 (3): 867-873.
- Benetos A, Lacolley P (2006). From 24-hour blood pressure measurements to arterial stiffness: a valid short cut? *Hypertension*, 47 (3): 327-328.
- Malhotra R, Nicholson C J et al (2022). Matrix Gla protein levels are associated with arterial stiffness and incident heart failure with preserved ejection fraction. *Arterioscler Thromb Vasc Biol*, 42(2):e61-e73.
- Murthy P K L, Sontake V, Tata A (2022). Human distal lung maps and lineage hierarchies reveal a bipotent progenitor. *Nature*, 604 (7904): 111-119.
- Lattanzi S, Brigo F, Trinka E et al (2019). Neutrophil-to-lymphocyte ratio in acute cerebral Hemorrhage: a system review. *Transl Stroke Res*, 10(2): 137-145.
- Hu W, Xin Y, Chen X et al (2019). Tranexamic acid incerebral hemorrhage: a meta-analysis

- and systematic review. *CNS Drugs*, 33(4): 327-336.
18. Sun G, Li X, Chen X et al (2019). Comparison of key hole endoscopy and craniotomy for the treatment of patients with hypertensive cerebral hemorrhage. *Medicine (Baltimore)*, 98 (2): e14123.
  19. Toyoda K, Koga M, Yamamoto H et al (2019). Clinical outcomes depending on acute blood pressure after cerebral hemorrhage. *Ann Neurol*, 85(9): 105-113.
  20. Repici A, Presbitero P, Carlino A, Strangio G (2010). First human case of esophagus-tracheal fistula closure by using a cardiac septal occluder. *Gastrointest Endosc*, 71 (4): 867-869.
  21. Tala H (1983). *Late bronze age and Iron Age I architecture in sagzabad-Qazvin plain –the central plateau of Iran*. *Iranica Antiqua*, 2(18): 17-51.
  22. Vidic B, Milisavljevic M (2017). *Atlas of the human body: Central nervous system and vascularization*. Academic press, pp.:20-257.
  23. Kiss F, Szentagothai J (1964). *Atlas of human anatomy: Nervous system – Angiology – Senseorgans*. Pergamon, pp.: 13-245.
  24. Fausett S R, Klingensmith J (2012). Compartmentalization of the foregut tube: developmental origins of the trachea and esophagus. *Wiley Interdiscip Rev Dev Biol*, 1(2): 184-202.
  25. Klales A R (2020). *Sex estimation of the human skeleton*. AP, pp.:50-300.
  26. Aufderheide A, Rodriguez-martin C (2006). *The Cambridge encyclopedia of human paleopathology*. Cambridge University Press, pp.: 175-417.
  27. Ortner D J (2003). *Identification of pathological conditions in human skeletal remains*. Smithsonian Institution NMNH, pp.: 153-268.
  28. Farhud D D, Azari M, Rahbar M (2024). Oral infections in ancient human skulls in 2000 BC/Iron Age, Iran. *Iran J Public Health*, 53 (5): 1115-1127.