



Tuberculosis in Human Bones from 4000 Years Ago, Iran

**Dariush D. Farhud*^{1,2,3}, *Mahsa Azari*^{2,3,4}, *Mehdi Rahbar*⁵

1. School of Public Health, Tebran University of Medical Sciences, Tebran, Iran
2. Research Center for Paleogenomics, Tebran University of Medical Sciences, Tebran, Iran
3. Dr. Farhud Genetics Clinic, Tebran, Iran
4. Department of Archeology, Faculty of Literature and Humanities, Tebran University, Tebran, Iran
5. Organization of Cultural Heritage, Handicrafts and Tourism, Tebran, Iran

*Corresponding Author: Email: farhud@sina.tums.ac.ir

(Received 18 Dec 2023; accepted 16 Feb 2024)

Abstract

Background: Tuberculosis is caused by a bacterium called *Mycobacterium tuberculosis*, which is a contagious and infectious disease; in the first stage, it destroys the lungs and in the next stage other body organs, such as the spine and long bones. This disease is transmitted through an infected person and due to the weakness of the immune system, the infection intensifies. Tuberculosis has two stages: low activity and high activity. In this article, we have discussed the signs of tuberculosis destruction with high intensity on the bones of prehistory human remains.

Methods: The examples of our research are related to human remains from the ancient cemetery of 4000 years ago from Sagezabad region of Qazvin Province of Iran. That period of history coincides with the Iron Age 2 and 3 in the region. People inside the Sagezabad cemetery were very near to early urban (the late rural) society.

Results: By matching the form of bone destruction with international atlases for tuberculosis, we have reached a satisfactory result in this article. Due to the strong penetration of the infection into the bones, destruction in the remains was high, so it has simplified the diagnosis for us.

Conclusion: We found tuberculosis among the bones. This common ancient disease existed even among Neanderthals.

Keywords: Paleopathology; Tuberculosis; Ancient skeletons; Human remains; Neanderthal; Iran

Introduction

Tuberculosis is a contagious and infectious disease that is transmitted from one person to another through coughing with small respiratory droplets that contain bacteria, by exhalation. Today, respiratory and infectious diseases are one of the main causes of human mortality (1). Tuberculosis affects the lungs in the first stage, but it can affect any part of the body through the blood-

stream and lymphatic vessels (2). Therefore, the disease appears in two ways in humans: 1- Pulmonary tuberculosis 2- Extra pulmonary tuberculosis. In pulmonary tuberculosis, lungs are the main site of *Mycobacterium tuberculosis* infection (3). When these bacteria enter the lungs by transferring to the lung with granuloma (small area of



inflammation) and cause infection, so this means powerful bacterial activity.

According to the resistance of the human immune system, two types of this disease can be distinguished: 1. Latent tuberculosis 2. Active tuberculosis (4).

In latent TB, the patient has a tuberculosis infection, but the bacteria in the patient's body are inactive and have no symptoms, also called inactive TB, is not contagious, but latent TB can become active. Therefore, a person may live with this disease for many years, but not be aware of the presence of *M. tuberculosis* bacteria in the body. In this cemetery, according to the remains of many people with severe symptoms of tuberculosis, it is possible that the type of tuberculosis is active tuberculosis.

Active TB: This disease, which is also called tuberculosis disease, shows the symptoms of the disease and in most cases, it can spread to others. This disease may occur weeks or years after infection with the TB bacteria (5). When a person has active tuberculosis, the symptoms of the disease are well known in the person and it has the ability to spread to others (6). Those who have a weaker

immune system are usually more exposed to this disease. In severe cases, this disease can affect other parts of the body, including the kidneys, spine or brain (7). When tuberculosis appears outside the lungs, like tuberculosis in the spine, it may change the shape of the bones of the vertebrae and the disc, and in the kidneys, it may cause blood in the urine. Weakness of the immune system is one of the factors that activate the disease in the body. A healthy immune system often successfully fights disease-causing bacteria, but the body does not always have strong enough immune cells to destroy the bacteria or virus. Lack of vitamins, lack of hygiene in the environment, war and the presence of numerous diseases, can weaken the power of immune cells (8).

Below is a sample of the lumbar vertebra of a patient with tuberculosis in Argentina in the year (905-1030 CE) (Fig. 1) (9). According to the remains of our research, which have the signs of war and war tools in the cemetery, the lack of nutrients due to war can be one of the causes of the disease, or perhaps it can be considered the cause of the activation of tuberculosis bacteria in the host's body.

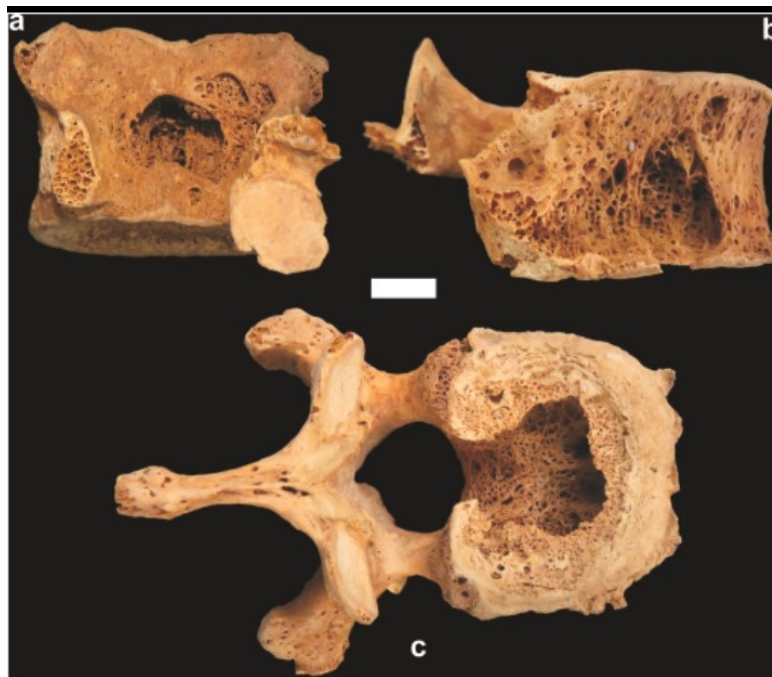

Fig. 1: Lumbar vertebrae of a person with tuberculosis (9)

Materials and Methods

Sagezabad cemetery is located in the southeast of Qazvin Province. Sagezabad hill is located near Sagezabad (Local and main pronunciation) cemetery, whose age is considered up to 9 thousand years (10). Other important hills whose names come next to Sagezabad hill, Ghabristan hill and Zagheh can be mentioned (11). The remains we studied from the Sagezabad cemetery were discovered and researched by one of the authors in the 2019 excavation gifts, symbols, decorations and burial rituals are very similar to the Medes period (12); In order to better understand the lifestyle, the complexity of the society and the beliefs of the people of that period, this type of research is needed. The period related to the

cemetery has been considered to be around Iron Age 2 and 3 (nearly 4000 years ago), according to the period and territory of the Medes kingdom and most likely its tribe was allied with the Medes government (13), but this did not mean the absence of war in the region. This cemetery consists of 5 layers, with the majority of human burials starting from the 4th layer. The 4th layer is related to the war layer, the burials along with the war tools are buried on the bones of the remains; from layer 3 to the layer below the soil surface, it is related to the remains with disease symptoms (Fig. 2). For this article, accurate international atlases were used to investigate the type of infection and with transparent adaptations, we achieved good results (14,15).

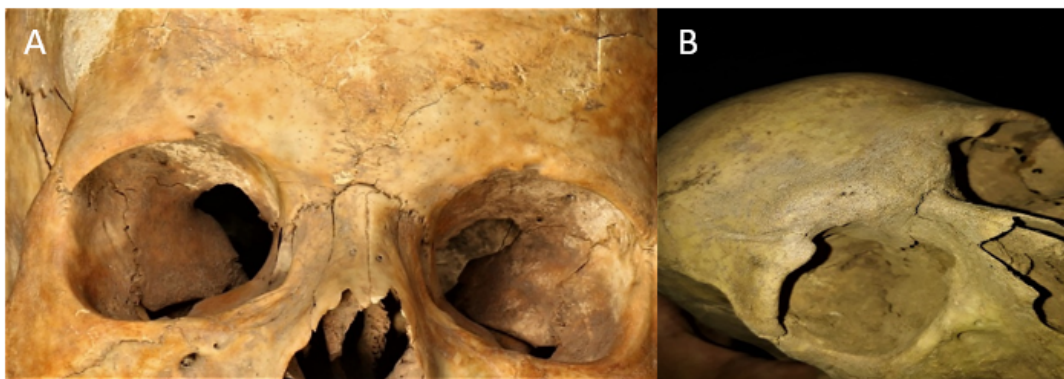


Fig. 2: A. The skull of an adult female with symptoms of vitamin deficiency in the forehead and anemia in the socket of the eye bone (Original). B. Skull of an adult male with a deep and repaired injury in the supra-orbital notch to up in bone; this skull has signs of another type of infection (Original).

Ethics approval

The relevant license was obtained from the Institute of Archeology of Tehran University with number 713/1798.

Results

In Fig. 3A, B we are facing a complete bone of an adult male and female, which has symptoms similar to the infectious disease of tuberculosis on the bone, which in an adult, these complications are related to the deformation of the whole body and most of the vertebrae. Severe corrosion

of the vertebra is mostly related to the cervical vertebrae and in the area of the spinous process, pedicle, transverse process and adult woman, it is not only related to the vertebrae and includes the curvature of the tibia, fibula, tarsal and carpal bones. As we can see in the Figure of the vertebrae in close up in Fig 3C, there is corrosion and deformation of the vertebral bones in the order of severity of axis, atlas, thoracic vertebrae, lumbar vertebrae and the whole part of a vertebra is involved in the disease. Of course, in Fig. A, it is possible that he is also suffering from another disease such as scoliosis along with the infection into the vertebra.

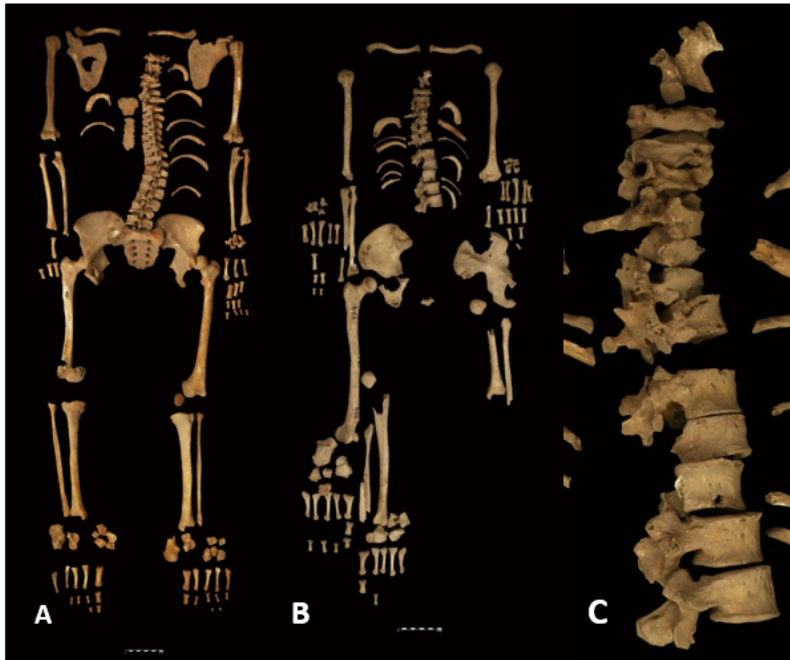


Fig. 3: A. Related to an adult man with complications to the vertebrae (Original). B. Related to an adult female, she has faced severe bone (Original). C. A set of beads related to an adult female, close up of Fig. B (Original)

Fig. 4: It is related to the burial of an adult woman that we saw a cavity in the body of the vertebra in the area of the lumbar vertebra and the

presence of an unusual distance and a crooked edge between the vertebrae.

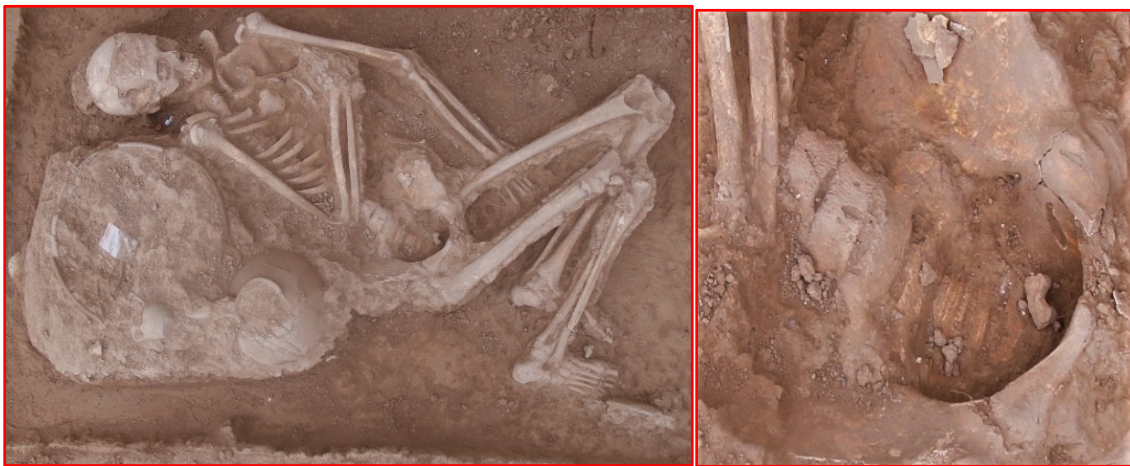

Fig. 4: Burial of an adult female with complications in the lumbar vertebra (Original)

Fig. 5 A: It is related to the calcaneus bone of an adult, which is very uneven and has calcification of the bone in the heel area and in the connecting

part of the talus, there is a bony protrusion which made impossible for person to move during person life, because the talus had no place to move

on the calcaneus. B. Corrosion and protrusion of bone edge of the lumbar vertebra, caused dentition, and there is also bone corrosion in other areas of the edge. C. The influence of an infection similar to tuberculosis on the person's vertebrae and sacrum, which changed the shape of the

bone, caused bone corrosion, calcification, and cavity formation. D. The sacrum of an adult female has calcification of bone destruction and blade – like appendage in the ilium to ischium and pubis.

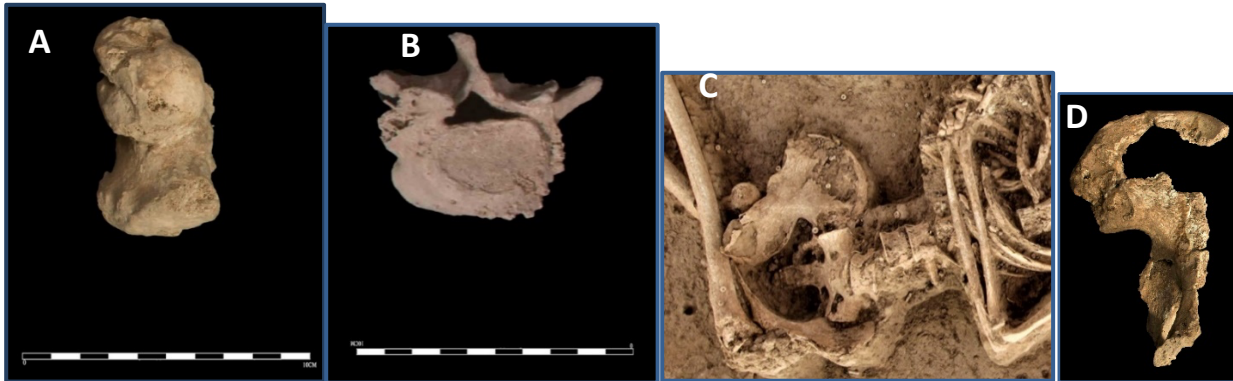

Fig. 5: A. An adult's calcaneus is swollen at the junction of the talus (Original). B. A vertebra related to an adult has corrosion and jagged edges due to infectious complications (Original). C. The person's spine and sacrum have severe infection similar to tuberculosis infection (Original). D. The sacrum of an adult female with severe infection (Original)

Fig. 6: Accessory process and mammillary process can be seen in the lumbar vertebra; The extreme deformity of the protrusion and indentation in the body, the calcification of the top of the vertebral bone, excessive compression and adhesion of the vertebrae in the lumber section

are clearly visible in Fig. A and B. C. The femur and patella is an adult person whose end of the femur bone and the entire patella have severe bone destruction. Deformity and bone protrusion is visible in some parts.




Fig. 6: A. Severe corrosion of the vertebral bones of an adult man (Original). B. Corrosion and severe locking vertebra of adult females due to complications of infectious disease (Original). C. Penetration of infection on the end of the femur and patella of an adult (Original)

It is possible that due to severe infection and bone destruction, this person was unable to walk

during lifetime and even bending the knee has been difficult for the person.

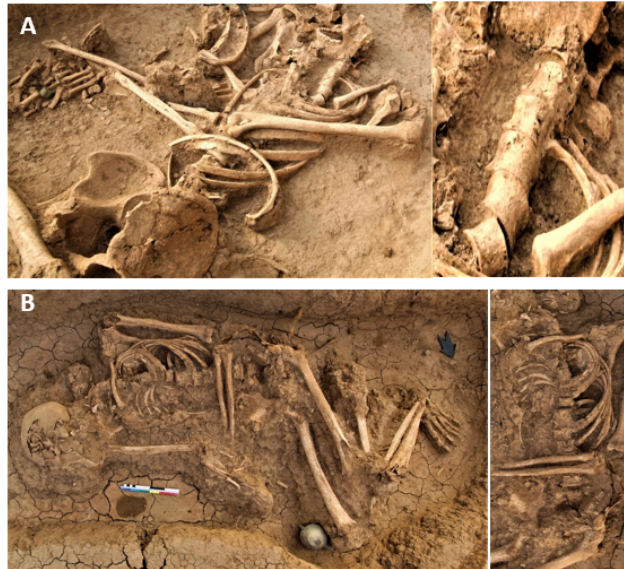

Fig. 7: A. The presence of cavities and corrosion of the edges of the vertebrae can be seen in the bone of an adult female (Original). B. Burial of an adult with infection in the spine, pelvis and ribs (Original)

Fig. 7 A: The burial is of an adult woman, where the presence of a hole on the body, unevenness on the edge of the vertebra, corrosion on the edge of the vertebra, the presence of trauma and calcification are visible. B. Burial of an adult with infection in the spine, pelvis and ribs has symptoms similar to tuber-

culosis infection. B. Some vertebrae are stuck together, there are signs of calcification and cavity, deformation and destruction on the bone in the rib bone, vertebrae, pelvis and also there are similar symptoms in the femur bone from the acetabulum.

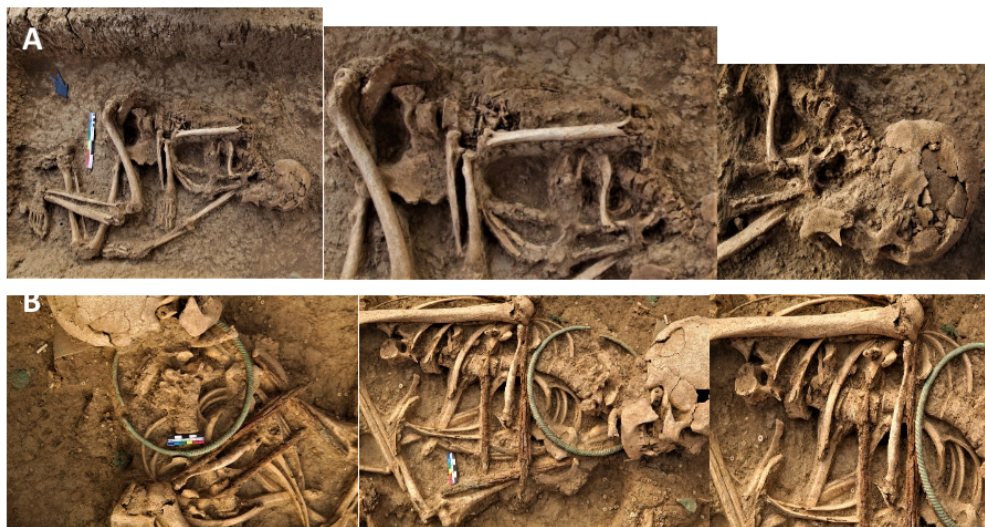

Fig. 8: A. severe corrosion and deformation of adult bones and vertebrae inside the burial (Original). B. vertebrae are stuck together and cavity in the spine of an adult female (Original)

Fig. 8 A: The burial is related to an adult human whose bone corrosion and deformation is from the first cervical vertebra to the last lumbar vertebra and pressure and corrosion to the superior particular process is very clear and visible. Most likely, based on the deformation of the vertebral bones, he was not able to stand. All visible symptoms in the ancient remains are very similar to the introduced samples related to tuberculosis disease (How to destroy the bones of the pelvis, ribs, vertebrae, long bones) in the matched atlases (14,15). Therefore, according to the age of the remains, which is 4000 years away from our time (16), this infection was deposited in their bodies and it has shown the effects of the disease on bones very clearly for the researchers. Due to the severe deformation of the bones of ancient people, so they were weak or dead due to this infection. B. The female spine and ribs are much damaged, the form of destruction is very similar to the effects of tuberculosis. Bone calcite, presence

of cavity, destruction of bone surface and penetration into bone tissue in some parts of the body can be symptoms of this infection. She was killed due to two war arrows; it is possible that it was difficult for this person to move with such a damaged spine. The cut of the surface of the vertebra can be seen by the arrow.

Fig. 9 A: The various bone fragments belong to a young adult, who probably died due to severe infiltration of the disease. The type of deformation of the vertebral bone body and destruction of the sacrum, coccyx, ilium to ischium, pubis, calcaneus, metatarsal/carpus are very similar to tuberculosis infection. B. The burial is for a young adult female. The signs of calcification and bone mass on the ribs indicate the presence of an infection in the lungs and frequent coughing during her lifetime. The type of symptoms and deformation of the vertebrae are all similar to tuberculosis infection.

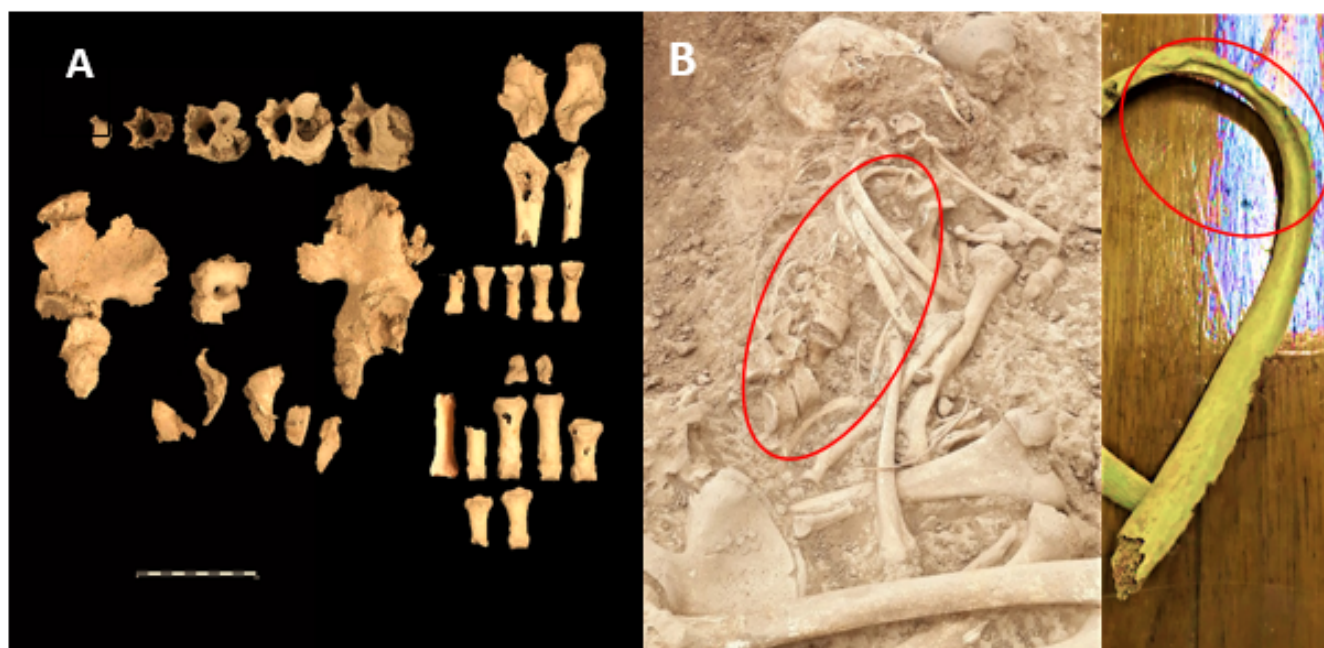


Fig. 9: A. Bone destruction of young adults with symptoms similar to tuberculosis infection (Original). B. The burial belongs to a young female who has evidence of deformity of the vertebrae and lung infection, so it is possible that she has tuberculosis (Original)

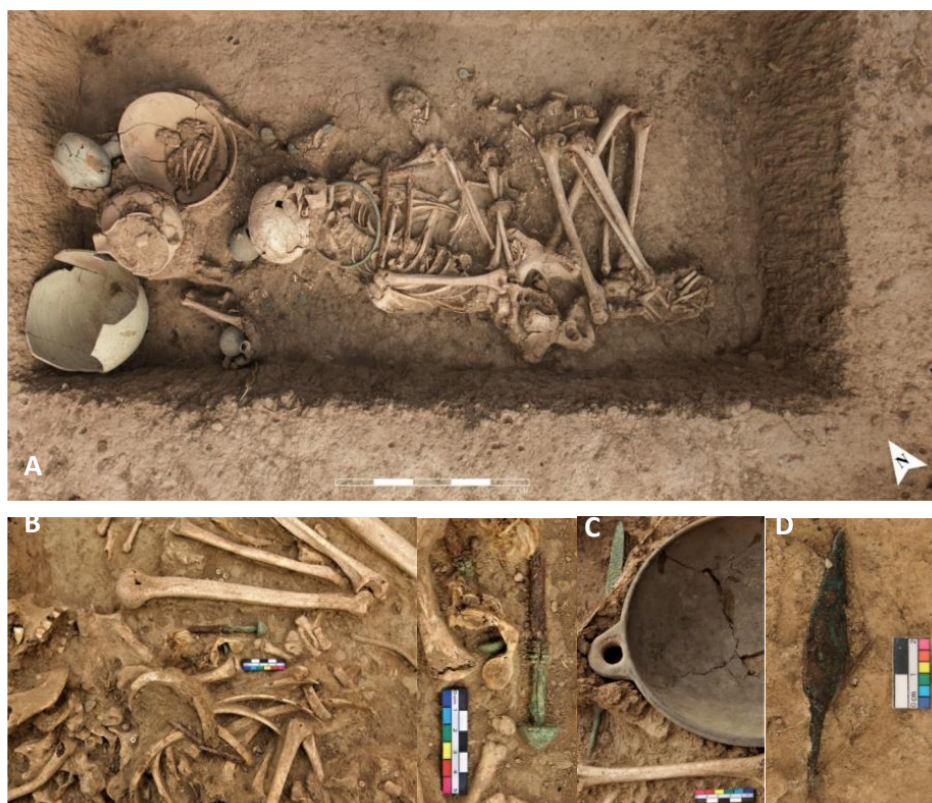

Fig. 10: A number of tools related to the war layer, which were among the bones of the dead (Original).

Discussion

Tuberculosis has two stages: 1. Latent 2. Obvious.

In the obvious stage, if the disease is not treated, the disease worsens and causes bone destruction. Considering the age of the remains, there is no doubt that there is no cure for this type of disease, and it is not unbelievable that the severity and destruction of bones in the body of the ancient host. According to the number of victims of this infection, this infection had spread rapidly due to the close relationship of people of this (tribe or village) with each other. Moreover, despite observing the signs of war tools (17) (Fig. 10) in the previous layer, it is possible that the war and looting of resources, lack of vitamins, lack of hygiene, and the severity of various infections in the body, have weakened immunity, so it may have caused get infected or the activation of inactive tuberculosis. According to the bacteria's

time to destroy the bones of the host, they have suffered from this disease until they died, and maybe this disease caused them to die (the early death). Another similar disease is malt fever, Brucellosis is a bacterial infection, transmitted from animals to humans and mostly through milk, cheese and other non-pasteurized dairy products (18). Tuberculosis disease is not only related to ancient people, this disease was also obtained from the bone remains of prehistoric humans; The remains of two Neanderthals in Subalyuk cave in northeastern Hungary show the presence of tuberculosis in the sacrum and skull bones (19-20). The symptoms of malt fever, like tuberculosis, involve the vertebrae and joints, but the intensity of bone changes in tuberculosis is greater than that of malt fever. All our statements are certain when be sampled and tested but to reach a 100% answer, genetic tests are needed, which are currently being done and the results will be published soon.

Conclusion

This research will help us to visualize the challenges of the ancients with this type of disease of their lifestyle. As mentioned in this research, tuberculosis is an infectious bacterial disease that has existed since prehistoric / ancient times and to this day also victims. Considering the geographical area of Iran and the fact that this country and the city under our research are in the center of transportation, there is a high possibility of this disease spreading from immigrants and travelers. Tuberculosis is a contagious infectious disease. When a person with tuberculosis coughs or sneezes, speaks or sings, the particles carrying the tuberculosis bacteria are scattered in the air. People who are nearby can get this infection by breathing in the bacteria. Due to the lack of food and the existence of war and the captivity of the people of Sagezabad, infectious bacteria had the opportunity to grow and operate at a high speed. Considering that the people of 4000 years ago were generally farmers, herders and potters, it is possible to imagine how much pain they endured without breaks, rest, and medicine. Seeing the cracks and changes in the bones of these ancient people shows the true, historical story is the kind of pain they suffer.

Journalism Ethical considerations

Ethical issues (Including plagiarism, informed consent, misconduct, data fabrication and/ or falsification, double publication and/ or submission, redundancy, etc.) have been completely observed by the authors.

Acknowledgements

The authors gratefully acknowledge the financial support for this work that was provided by Dr. Farhud Scientific Foundation.

Conflict of interest

The authors declare that there is no conflict of interest.

References

1. Zink A R, Molnar E, Motamedi N (2007). Molecular history of tuberculosis from ancient mummies and skeletons. *Int J Osteoarchaeol*, 17 (4): 380-391.
2. Donoyhue H D (2011). Insights gained from paleomicrobiology into ancient and modern tuberculosis. *Clin Microbiol Infect*, 17(61): 821-829.
3. Morse D, Brothwell D R, Ucko P J (1964). Tuberculosis in ancient Egypt. *Am Rev Respir Dis*, 90: 524-541.
4. Barberis I, Bragazzi N L, Galluzzo L (2017). The history of tuberculosis: from the first historical records to the isolation of Koch's bacillus. *J Prev Med Hyg*, 58(1): E9-E12.
5. Sudre P, Dam G T, Kochi A (1992). Tuberculosis: a global over view of the situation today. *Bull World Health Organ*, 70(2):149-59.
6. Tavaziva G, Harris M, Abidi S K (2022). Chest X-ray analysis with deep learning- based software as a triage test for pulmonary tuberculosis: an individual patient data meta-analysis of diagnostic accuracy. *Clin Infect Dis*, 74(8):1390-1400.
7. Miglior G B, Wu SJ, Mattelli A (2022). Clinical standards for the diagnosis, treatment and prevention of TB infection. *Int J Tuberc Lung Dis*, 26 (3): 190-205.
8. Floyd K, Glaziou P, Zumla A (2018). The global tuberculosis epidemic and progress in care, prevention, and research: an overview in year 3 of the end TB era. *Lancet Respir Med*, 6(4): 299-314.
9. Luna L H, Aranda C M, Santos A L et al (2020). Oldest evidence of tuberculosis in Argentina: A multidisciplinary investigation in an adult male skeleton from Saujil, Tinogasta, Catamarca (905-1030 CE). *Tuberculosis (Edinb)*, 125:101995.
10. Ghodusian T, Samadi A, Talaei H (2017). Analyzing aspects of the ancient metallurgy of the Qazvin plain based on the metal data discov-

- ered in Iron Age 2 graves of Segzabad cemetery. *J Archaeological Studies*, 9 (1): 167-183.
11. Tuplin C (2004). *Medes in Media, Mesopotamia, and Anatolia: empire, hegemony, domination or illusion?*. Ancient West & East, pp.: 223-251.
 12. Summers G D (1997). The identification of the Iron Age city on Kerkenes Dag in central Anatolia. *Journal of Near Eastern Studies*, 56 (2): 81-94.
 13. Mirwaisi H F (2010). *Return of the Medes: An analysis of Iranian history*. Wheatmark, pp.: 49-258.
 14. Aufderheide A, Rodriguez-martin C (2006). *The Cambridge encyclopedia of human paleopathology*. CUP, pp.: 175-417.
 15. Ortner D J (2003). *Identification of pathological conditions in human skeletal remains*. Smithsonian Institution NMNH. pp.: 153-268.
 16. Farhud D D, Azari M, Rahbar M (2024). Oral infections in ancient human skulls in 2000 BC/Iron age, Iran. *Iran J Public Health*, 53(5):1115-1127.
 17. Farhud D D, Azari M, Rahbar M (2024). Tracking of infectious diseases and deadly injuries through signs observed in excavated human skeletons of 2000 BC/Iron Age in Iran. *Iran J Public Health*, 53(7):1598-1611.
 18. Dehkordi M, Gasemian S O, Ahangaran M (2022). The relationship between some risk factors and seroconversion to brucellosis in Gachsaran, Iran. *Journal of Zoonotic Diseases*, 6 (2): 84-90.
 19. Lee O, Wu H H, Besra G S et al (2023). Sensitive lipid biomarker detection for tuberculosis in late Neanderthal skeletons from Subalyuk Cave, Hungary. *Tuberculosis (Edinb)*, 143S:102420.
 20. Farhud D D, Azari M, Mehrabi A (2022). The history of corona virus, from Neanderthals to the present time: A Brief Review. *Iran J Public Health*, 51(3):531-534.