

## PARAGONIMUS AND PARAGONIMIASIS

Muneo Yokogawa

Department of Parasitology, School of Medicine,  
Chiba University, Chiba, Japan

### I. Species of *Paragonimus* with their geographical distribution;

*Paragonimus* infection is found in a wide variety of mammals which feed on fresh-water crabs or crayfish. However, in man it is limited to places where food habits make infection possible. (Fig. 1)

At present 31 species of *Paragonimus* have been reported in various mammals in many countries. Some of them may be synonyms rather than separate species as shown in Table 1.

The species whose life cycle are fully known are *P. westermani*, *P. kelli-cotti*, *P. ohirai*, *P. iloktsuenensis*, *P. skrjabini* (*P. szechuanensis*), *P. miyazakii*, *P. heterotremus* (*P. tuanshanensis*), *P. mengalensis* and *P. sadoensis* (Table 2).

It is generally accepted that the arrangement of spines, the shape of the ovary and the testes, the character of eggs and the relative size of the oral and ventral suckers are good criteria for differentiating adult species, but no one of them can be used independently as the sole criterion. (Fig. 2)

Among those species *P. westermani* was thought to be the only species that develops in man. Such a view is no longer acceptable due to the accumulation of new knowledge of the taxonomy, life history and host-parasite relationships as well as the distribution of the *Paragonimus* worms. At present six species besides *P. westermani* were known as the causative agents of human paragonimiasis.

And some of them are causing particular symptoms which are conspicuously different from the idea of paragonimiasis described in the textbook.

In China, 14 species of *Paragonimus* have been reported and among them *P. skrjabini* (*P. szechuanensis*), and *P. tuanshanensis* are known as etiologic agents of human paragonimiasis in addition to *P. westermani*.

In Africa, paragonimiasis is widespread and is mostly, if not entirely, indigenous. A new species *P. africanus*, has been found in West Cameroon as an etiologic agent of human paragonimiasis.

the eating of raw or imperfectly cooked crabs.

However, another possible mode of human infection is an accidental transfer of the encysted metacercariae to the mouth through the handling of crabs while preparing them as food. (Yokogawa, 1952; Yogore, 1957).

### III. Symptomatology:

The most noticeable symptoms of paragonimiasis due to *P. westermani* and some other species are cough and blood-stained sputum, with typical *Paragonimus* eggs. Owing to its pathogenicity in the lungs, paragonimiasis may be suggestive of pulmonary tuberculosis. It has been reported in various countries that an unexpectedly large number of cases in the endemic areas have been wrongly diagnosed as pulmonary tuberculosis and were treated with drugs appropriate to that disease.

However, the most characteristic clinical features due to *P. szechuanensis* (*P. skrjabini*) in China are migrating subcutaneous nodules and high eosinophilia, but cough is not common and often not severe; sputum is generally scanty and *Paragonimus* eggs are, as a rule, not present. The nodules are most commonly found in the abdominal wall. (Wang et al., 1964).

*Paragonimus tuanshanensis* is suspected to be pathogenic to man and responsible for the occurrence of most, if not all, human cases of paragonimiasis in China (Chung et al., 1964). It is considered that although it is true that clinical cases in the area have symptoms of chronic cough, expectoration, chest pain, hemoptysis etc., resembling those due to *Paragonimus westermani*, yet the absence of *Paragonimus* eggs in the sputum would be different from *P. westermani*.

Recently the immature worms removed from the subcutaneous swellings of a patient in Thailand were identified as *P. heterotremus* \* (Miyazaki and Harinasuta, 1966). The patient was a 13-year-old who was suffering chiefly from chest pains for 1 year and eosinophilia were as high as 48%. However, *Paragonimus* eggs were not found in sputum and feces.

The most noticeable symptoms of *Paragonimus miyazakii* infection in man recently found in Japan are spontaneous pneumothorax, bronchitis, exudative pleurisy and eosinophilia as high as 20-70% but cough is not common. *Paragonimus* eggs are not found in the sputum and feces. No abnormal shadows of worm cyst in the lungs such as nodular or ring shadow were found by chest X-Ray examination. (Table 3)

All those paragonimiasis patients in Africa and South America suffered from chronic coughs and discharged blood in sputum, with typical *Paragonimus* eggs.

As mentioned above, it is interesting that clinical symptoms of paragonimiasis are quite different according to the species of *Paragonimus* that

\* Miyazaki and Harinasuta (1966) considered to be identical with *P. tuanshanensis*.

cause paragonimiasis in man.

#### IV. Diagnosis:

##### 1. *Clinical and Parasitological examinations*

Paragonimiasis *westermani* in endemic areas can be diagnosed clinically by an occasional light cough and yellowish-brown pus-like sputum in which bloody spots or lines can sometimes be seen. The eggs of *Paragonimus* can be found in blood-stained sputum of patients by the direct smear technique, but when eggs are few the centrifugation technique with 1-2 percent sodium hydroxide should be used. In light infection, however, sputum is not always produced, and in those patients who swallow it, the eggs can be found only by examination of the stool.

##### 2. *Sero-immunological techniques*

Sero-immunological techniques such as Interdermal test (IDT), Complement fixation test (CF-T), Gel-diffusion test (Ouchterlony test) and immunoelectrophoresis can be widely used as indicated below.

###### 1) Intradermal Test

a) An intradermal test for paragonimiasis is easily carried out, and there are no side effects, so the test is, therefore, useful as a screening method for *Paragonimus* infections of man in endemic areas.

b) However, as the intradermal test continues to show positive reactions for as long as 10-20 years after complete recovery, a positive dermal reaction does not always mean the present infection.

Clinically, the intradermal test is also useful in differentiating paragonimiasis from tuberculosis and some other chest diseases or cerebral paragonimiasis from brain tumor or cerebral hemorrhage. If the intradermal test gives negative results, *Paragonimus* infection can almost certainly be ruled out.

c) An intradermal test shows cross reactions with *P. westermani* and other species of *Paragonimus*, therefore, this test can not be used for differentiation of the species of *Paragonimus* as causative agent of paragonimiasis.

###### 2) Complement fixation test (CF-T)

The complement fixation test for paragonimiasis is closely correlated with the existence of infection and not past infections. Therefore, for the epidemiological surveys the intradermal test should be used first and the complement fixation test should be performed on individuals with positive dermal reactions.

The complement fixation test can also be used as a criterion of cure of paragonimiasis after treatment. (Yokogawa et al., 1962).

Very recently, the author et al. found that complement fixation test can also be used for differential diagnosis between paragonimiasis *westermani* and paragonimiasis *miyazakii*. All of 10 cases of paragonimiasis *miyazakii* showed positive reaction with high antibody titer for the complement fixation test with the antigen prepared from the adult worms of *P. miyazakii* while 4 out of 10 showed negative for the complement fixation test with the antigen from *P. westermani* and the antibody titers of 6 positive cases with *P. westermani* antigen were much lower than those with the *P. miyazakii* antigen.

### 3) Immunoelectrophoresis

Immunoelectrophoresis is now widely applied to the diagnosis of paragonimiasis. Specific bands were detected in the sera of paragonimiasis patients with the antigen prepared from *P. westermani*. (Biguet et al., 1965; Yogore et al., 1965).

The immunoelectrophoretic technique was also applied to the differentiation of the species of *Paragonimus* and the different precipitin patterns were shown in respective antigen-antibody systems of *P. westermani*, *P. ohirai*, *P. miyazakii* and *P. sadoensis*.

The specific bands of each species were also proved by saturation method. (Tsuji et al., 1967; Yokogawa et al., 1968).

Very recently, Yokogawa et al. applied the immunoelectrophoretic technique and Ouchterlony test to the patient serum suspected of *P. miyazakii* infection and proved that these techniques are effective in identifying the species among *P. westermani*, *P. miyazakii* and *P. ohirai*.

The serum of the patient with *P. miyazakii* showed considerably strong immunoserological cross-reaction to *P. ohirai* antigen. But cross-reaction with *P. westermani* antigen was weaker and the precipitation bands with *P. miyazakii* antigen were shown even in dilution of serum as high as 1/40 - 1/80.

On the other hand, the serum of the patients with *P. westermani* showed almost the same patterns of precipitin bands with those three antigens. This is interesting, in view of near kinship of those three species.

### 4) Agar double diffusion test (Ouchterlony test)

Recently, Yokogawa et al. also proved that Ouchterlony test is effective to differentiate the species between *P. westermani* and *P. miyazakii* infections in man.

It is of interest to note that the species of *Paragonimus* causing paragonimiasis in man can be differentiated with CF-T, Ouchterlony test and immunoelectrophoresis.

### 3. Radiography

Numerous studies have been reported on the use of X-ray pictures for the diagnosis of pulmonary paragonimiasis due to *P. westermani*. It is not easy to diagnose paragonimiasis solely by chest X-ray examinations, particularly to differentiate it from pulmonary tuberculosis. Most of the abnormal shadows in paragonimiasis are found in the middle, upper and lower parts of the lungs, but are rarely in the apex.

The nodular worm-cyst shadow which has a sharply marked round or oval contour is suggestive of a tuberculoma. The ring shadow is a cystic form with a relatively thin wall and is round, oval or irregular in shape. These shadows which are supposedly typical for paragonimiasis occurred in less than 50% of the patients with paragonimiasis, and nearly 40% of the X-rays could hardly be distinguished from those of pulmonary tuberculosis.

In paragonimiasis *miyazakii* spontaneous pneumothorax and exudative pleurisy are usually seen by chest X-ray examination.

### V. Treatment

For paragonimiasis, bithionol seemed to be the most effective of any drugs which have ever been tested. (Yokogawa et al., 1961). Reports of clinical cure rates of pulmonary paragonimiasis after treatment with bithionol vary from 84% (Wang et al., 1964) to 100% (Kang et al., 1963).

Diarrhoea, loose stools, abdominal pain, nausea, vomiting and urticarial eruption have been mentioned as the side effects of bithionol, however, all these side effects were transient and did not necessitate any symptomatic treatment.

It has been reported that bithionol was not effectual against immature worms in the pleural or peritoneal cavities (Yokogawa et al., 1961; Waitz et al., 1963).

In the case of paragonimiasis *miyazakii*, the treatment with a daily dose of 30mg/kg on alternate days for a total ten to 15 doses seemed not to be enough and at least two treatments seemed necessary.

As for the internal treatment of extrapulmonary paragonimiasis, especially cerebral involvement, it has been suggested that good results can be expected with bithionol. (Kitamura and Nishimura, 1963; Shim et al., 1964; Wang et al., 1964; Oh, 1967).

Bithionol is also effective for cutaneous paragonimiasis. Wang et al. (1964) treated subcutaneous swelling due to *P. skrjabini* with a dose 50mg/kg of bithionol orally every other day for 20 days. They reported that subcutaneous swellings in all 24 cases gradually diminished in size and finally disappeared after completion of treatment, and that 3 cases relapsed 4, 5 and 9 months after treatment, but all of them were completely cured after

the second course of treatment.

## VI. Control

While the control of trematode infections by the elimination of the vector snails through use of chemicals or habitat alteration has been frequently suggested, it seems that this method has limited application in control of paragonimiasis.

The killing of the crabs that transmit the infection to man has been also suggested, but this method would be difficult to apply in most of the endemic areas, and it is doubtful that it has actually been used extensively as a control measure. Successful mass treatment with bithionol would be of great value as a control measure only where most of the snail intermediate hosts are infected from human sources.

The possibility of infection from cysts freed from crabs during food preparation was mentioned. Efforts to induce people to be more careful in handling the crabs while preparing them could reduce this danger.

## REFERENCES

- Biguet, J. et al. (1965): Contribution de l'analyse immuno-electrophoretic a la connaissance des antigenes vermineux. Incidence partique sur leur standardization leur purification et le diagnostic des helminthiasis par immuno-electrophorese. *Revue d'Immunologie, Paris.* 29, 5-30.
- Cevallos, V.A. and Segovia, A. (1957): Doce casos de paragonimiasis en ninos manabitas. *Rev. Ecuat. Pediat.*, 9, 51-59.
- Chung, H.L. et al. (1964): Chemotherapy of paragonimiasis. *Chin. Med. J.*, 74, 1-16.
- Kang, S.Y. et al. (1963): An experimental study on chemoprophylaxis in paragonimiasis. *Korean Med. J.*, 6, 833-840.
- Kitamura, K. and Nishimura, K. (1963): Diagnosis and Treatment of cerebral paragonimiasis. *Clin. Neurol.*, 3, 376-381.
- Larch, C.J. (1968): Paragonimiasis pulmonar. (Presentacion de un caso). *Rev. Med. Hondurena.* 34, 111-114.
- Little, M.D. (1968): *Paragonimus caliensis* sp and paragonimiasis in Colombia. *J. Parasit.*, 54, 738-746.
- Martinez Baez, M. and Jimenez Gelan, A. (1961): Un caso de trematodiasis pulmonar registrado en Mexico. *Inst. Salubr. Enferm. Trop. Mexico.*, 27, 101-114.
- Mozzotti L. and Miyazaki I. (1965): The first record of adult lung flukes *Paragonimus* in Mexco (Trematoda: Troglotrematidae). *Jap. J. Parasit.*, 14, 34-36.
- Miyazaki, I. and Harinasuta, C. (1966): The first case of human paragonimiasis caused by *P. Heterotremus* Chen, et Hsia, 1964. *Ann. Trop. Med.*

- Parasit.*, 60, 509-514.
- Miyazaki, I. and Ishii, Y. (1968): Studies on the Mexican lung flukes with special reference to a description of *Paragonimus mexicanus* sp. nov. (Trematoda: Troglotrematidae). *Jap. J. Parasit.*, 17, 445-453.
- Nwakolo, C. (1972): Outbreak of paragonimiasis in Eastern Nigeria. *Lancet* Jan., 1, 1972, 32-33.
- Oh, S.J. (1967): Bithionol treatment in cerebral paragonimiasis. *Amer. J. Trop. Med. Hyg.*, 16, 585-590.
- Rodriguez, M.J.D. (1963): Contribucion al estudio del ciclo evolutivo del *P. westermani* (Kerbert, 1878) Braun, 1899. *Rev. Ecuat. Med. Sci. Biol.*, 1, 20-34.
- Shim, B.S. et al. (1914): Clinical observation on the chemotherapy of cerebral paragonimiasis with bithionol. *Korean central J. Med.*, 7, 757-764.
- Tsuji, M. et al (1967): Studies on the comparison of antigenic structure of three species of *Paragonimus* (*P. westermani*, *P. miyazakii* and *P. ohirai*) in immunoelectrophoresis. *Jap. J. Parasit.*, 16, 541-542.
- Waitz, J.A. et al. (1964): Effects of bithionol against *Paragonimus kellicotti* in Rats. *Amer. J. Trop. Med. Hyg.*, 13, 584-588.
- Wang, C.H. et al. (1964): The clinical manifestations and bithionol therapy of paragonimiasis in Szechuan province. *Chin. Med. J.*, 83, 163-170.
- Yogore, M. (1957): Studies on paragonimiasis in the Philippines. 1. *Philipp. J. Science.*, 86, 37-46.
- Yogore, M. et al. (1965): Immunodiffusion studies on paragonimiasis. *Amer. J. Trop. Med. Hyg.*, 14, 586-591.
- Yokogawa, M. (1952): Epidemiology of paragonimiasis. *Koshu Eisci*, 2, 19-26.
- Yokogawa, M. (1965): *Paragonimus* and paragonimiasis. *Advances in Parasitology.*, 3, 99-153.
- Yokogawa, M. (1966): Epidemiology and control of Paragonimiasis. *World Health Organization. Hel./Wp/66.9.*
- Yokogawa, M. (1969): *Paragonimus* and paragonimiasis. *Advances in Parasitology*, 7, 375-387.
- Yokogawa, M. et al. (1962): Studies on the complement fixation test for paragonimiasis as the criterion of cure. *Jap. J. Parasit.*, 11, 117-122.
- Yokogawa, M. et al. (1968): Studies on the antigenic structure of *Paragonimus* from Sado in immunoelectrophoresis. *Jas. J. Parasit.*, 17, 295-296.
- Yokogawa, S. et al. (1960): *Paragonimus* and paragonimiasis. *Exp. Parasit.*, 10, 81-137; 139-205.

TABLE 1. SPECIES OF PARAGONIMUS (PROPOSED BY)

- P. AUDIS (HIESING, 1850)
- P. COMPACTUS (COBBOLD, 1859)
- P. WESTERMANI (KERBER, 1878)
- P. RINGHERRI (COBBOLD, 1880)\*
- P. PULMONIS (NAKANAMA, 1885)
- P. PULMONALIS (BAELZ, 1883)\*
- P. VELLICOTTI (WARD, 1908)
- P. EDWARDSI (GULATI, 1962)\*
- P. OHIRAI (MIYAZAKI, 1939)
- P. FLOKTSUENENSIS (CHEN, 1940)
- P. MACACAE (SANDOSHAM, 1953)\*
- P. SKRJABINI (CHEN, 1959)
- (P. SZECHUANENSIS (CHUNG AND Ts'AO, 1962))
- P. YUNNANENSIS (HO ET AL., 1959)
- P. MIYAZAKII (KAMO ET AL., 1961)
- P. MACROCHIS (CHEN, 1962)
- P. FUKIENSIS (TANG AND TANG, 1962)
- P. CHENI (HU, 1963)
- P. HETEROPTREMUS (CHEN AND HSIA, 1964)
- (P. TUANSHANENSIS (CHUNG ET AL., 1964))
- P. PROLIFERUS (HSIA AND CHEN, 1964)
- P. MENGALENSIS (CHUNG ET AL., 1964)
- E. SKRJABINI (CHEN, 1965)\*\*
- P. SIAMENSIS (MIYAZAKI AND WYKOFF, 1965)
- P. AFRICANUS (VOELKER AND VOGEL, 1965)
- P. UTEROBILATERALIS (VOELKER AND VOGEL, 1965)
- P. BANGKOKENSIS (MIYAZAKI AND VAJRASTHIRA, 1967)
- P. HATHASUTAI (MIYAZAKI AND VAJRASTHIRA, 1968)
- P. SADOENSIS (MIYAZAKI ET AL., 1968)
- P. CALIENSIS (LITTLE, 1968)
- P. MEXICANUS (MIYAZAKI AND ISHII, 1968)
- P. PERUVIANUS (MIYAZAKI, IBANEZ AND NIRANDA, 1969)

- \* APPEARS TO BE IDENTICAL WITH P. WESTERMANI
- \*\* EUPARAGONIMUS

TABLE 2. LIFE CYCLE OF PARAGONIMUS

SPECIES	1ST INT. HOST	2ND INT. HOST	DEFENSITIVE NEST AREAS
P. WESTERMANI*	CEPHALOSCOPIA SP.	POTAMON SP., LEUCODIPLO SP., PROGAMBEUS SP.	IND. CAT. DOG. HIGER AREA
P. FUKIENSIS	TRICHOLOPIA LUTEA	CHAMBERUS SP.	IND. CAT. DOG. PIG AMERICA
P. OHIRAI	ASSIMINA SP.	SESIPIA SP.	RAT. BADGER. WEASEL JAPAN, CHINA
P. FLOKTSUENENSIS	TRICHOLOPIA SP.	SESIPIA SP., POTAMON SP.	RAT. CHINA, JAPAN, TAIWAN, KOREA
P. SIAMENSIS	ASSIMINA LUTEA	POTAMON SP.	DOG. CHINA
P. SIKHIANI	TRICHOLOPIA GREGORIANA	POTAMON SP.	IND. CAT. DOG. CHINA
(P. SZECHUANENSIS)	TRICHOLOPIA GREGORIANA	POTAMON SP.	FAUNA LAPAVATA CHINA
P. MIYAZAKII*	TRICHOLOPIA (OUREA) NIPPONICA AND KOSHIKENSIS	POTAMON TERAMAI	IND. BADGER. RAT. JAPAN
P. HOSOKUBI	TRICHOLOPIA GREGORIANA	POTAMON SIKHIANI	RAT. CHINA
P. CHENI	TRICHOLOPIA GREGORIANA	POTAMON DEUTELICATUS	RAT. CAT. CHINA
(P. SZECHUANENSIS)	TRICHOLOPIA GREGORIANA	POTAMON SP.	IND. RAT. DOG. PIGLET. LEOPARD. CHINA, THAILAND
P. FUKIENSIS	TRICHOLOPIA GREGORIANA	POTAMON SP.	RAT. CHINA
P. MACROCHIS	TRICHOLOPIA GREGORIANA	POTAMON SP.	CAT. DOG. CHINA
P. FUKIENSIS	TRICHOLOPIA GREGORIANA	SESIPIA SP.	IND. MONOGOL. DOG. AFRICA
P. HATHASUTAI	TRICHOLOPIA GREGORIANA	SESIPIA SP.	MONOGOL. DOG. AFRICA
P. SIAMENSIS	TRICHOLOPIA GREGORIANA	PARATRIPLAXA GREGORIS	CAT. THAILAND
P. HATHASUTAI	TRICHOLOPIA GREGORIANA	POTAMON SIKHIANI	MONOGOL. BANGLADESH
P. SADOENSIS	TRICHOLOPIA GREGORIANA	POTAMON SIKHIANI	THAILAND
P. CALIENSIS	TRICHOLOPIA GREGORIANA	SESIPIA SP.	WEASEL JAPAN
P. MEXICANUS*	TRICHOLOPIA GREGORIANA	SESIPIA SP.	OPUSSORUS CALIFORNIA
P. PERUVIANUS*	TRICHOLOPIA GREGORIANA	SESIPIA SP.	IND. OPUSSORUS PERU
P. PERUVIANUS*	TRICHOLOPIA GREGORIANA	SESIPIA SP.	IND. CAT. PERU

\* CAUSATIVE AGENT OF HUMAN PARAGONIMIASIS.

TABLE 3. CASE OF PARAGONIMIASIS MIYAZAKII

CASE NO.	NAME	SEX	AGE	MAIN SYMPTOMS	EOSINOPHILIA	NO. OF PRECIPITIN BANDS IN IMMUNOELECTROPHORESIS	
						P.W	P.M
1	H. H. (USHIODA HOSP.) (DEC. 1969)	M	30	BRONCHITIS EX. PLEURITIS	20-50%	1) x 18.9 2) -	5 x 16.2
2	Y. S. (KAWASAKI-DAISHI HOSP.) (DEC. 1969)	M	42	PNEUMOTHORAX EX. PLEURITIS	60-65%	1) - 2) -	x 110.2 x 11.7
3	A. N. (MITSUI MEMORIAL HOSP.) (MAY. 1972)	M	34	PNEUMOTHORAX EX. PLEURITIS	27-56%	1) x 28.8 2) -	x 160 x 12.3
4	S. S. (SAISEI-KAI CENTRAL HOSP.) (DEC. 1972)	M	33	PNEUMOTHORAX EX. PLEURITIS	20%	1) x 94.8 2) x 12.2	x 160 x 38.1
5	Y. N. (YOKOHAMA CITIZEN'S) (MAY. 1972)	F	44	PNEUMOTHORAX EX. PLEURITIS	29-66%	1) - 2) -	x 55.0 x 32.5
6	M. S. (NAGAHAMA SANAT. KAWAGAHARA) (OCT. 1973)	M	44	PNEUMOTHORAX EX. PLEURITIS	25-31%	1) x 10.0 2) -	x 96.4
7	T. O. (YAMANASHI CENTRAL HOSP.) (DEC. 1973)	M	40	PNEUMOTHORAX EX. PLEURITIS	22-48%	1) x 160 2) x 61.3	x 160 x 146.9
8	I. I. (YAMANASHI CENTRAL HOSP.) (DEC. 1973)	M	50	PNEUMOTHORAX EX. PLEURITIS	17-34%	1) x 137.7 2) x 84.8	x 160 x 160
9	Y. H. (MEDICAL INST. TOKYO UNIV.) (1972)	M	40	PNEUMOTHORAX EX. PLEURITIS	7%	1) x 69.2 2) -	x 160 x 27.6
10	H. S. (MITSUI MEMORIAL HOSP.) (DEC. 1970)	M	27	EX. PLEURITIS	38%	1) x 62.5 2) -	

- EX. PLEURITIS --- EXUDATIVE PLEURITIS
- \* PLEURAL EFFUSION 1) BEFORE TREATMENT  
2) AFTER TREATMENT
- \*\* PARAGONIMUS EGGS IN PLEURAL EFFUSION.
- \*\*\* DATE OF AN ATTACK OF THE DISEASE.



An outbreak of paragonimiasis in eastern Nigeria has been reported during the civil war and post-war period from 1967 to 1970 (Nwakolo, 1972). The species of *Paragonimus* in this area is not yet known.

In Mexico, adult lung flukes were found in the lungs of opossum *Didelphys marsupialis* captured in Colima on the Pacific coast (Mazzotti and Miyazaki, 1965) and they were described as a new species, *P. mexicanus* (Miyazaki and Ishii, 1968). The eggs found in lung tissue excised from a male Mexican patient were reconsidered to belong to this new species, but no larval stages of *Paragonimus* have ever been found. (Martinez Baez and Jimenez Galan, 1961).

In Colombia adult worms of *Paragonimus* found from the lungs of the opossums were described as a new species, *P. caliensis* (Little, 1968).

In Peru many cases of paragonimiasis have been reported. They were once assumed to be due to *P. westermani* but the discovery of a new species, *P. peruvianus* (Ibanez and Miranda, 1967; Miyazaki et al., 1969) and the finding of *Paragonimus* eggs unlike those of *P. westermani* in the sputum of the patients make it doubtful that *P. westermani* occurs at all in Peru. (Miranda et al., 1967).

In Ecuador, human paragonimiasis was first observed by Heinert in 1921, and has since been found throughout the coastal region (Cevallos and Segovia, 1957 and Rodriguez, 1963). Very recently, in summer of 1971 a different type of metacercaria of *Paragonimus* from that of *P. westermani* was found in a freshwater crab, *strengeria eigenmanni*, Collected at Caluma (Yokogawa et al., 1972). It is suspected now that human paragonimiasis is caused by other species than *P. westermani* in Ecuador.

In Honduras the eggs of *Paragonimus* sp. were found in the sputum of a patient by Larch (1968).

In Japan, besides *Paragonimus westermani*, four species of *Paragonimus* that is *P. ohirai*, *P. iloktsuenensis*, *P. miyazakii* and *P. sadoensis* have been found in the lungs of rats, dogs, pigs, wild boars and other wild animals, but no human infections with those species have been reported yet. However, human infections with at least two species i.e., *P. miyazakii* and *P. sadoensis* have long been suspected, on the basis that their second intermediate host is *Potamon dehaani*, which is habitually eaten uncooked or pickled in some areas, in Japan.

Very recently many cases of paragonimiasis showing quite different symptoms from those of paragonimiasis *westermani* were reported in Japan. These cases were diagnosed mainly with immuno-serological methods as paragonimiasis due to *Paragonimus miyazakii*.

## II. Mode of human infection:

The most important mode of human infection with *P. westermani* or other species of *Paragonimus* throughout the endemic areas is undoubtedly

Fig.1 Distribution of paragonimiasis

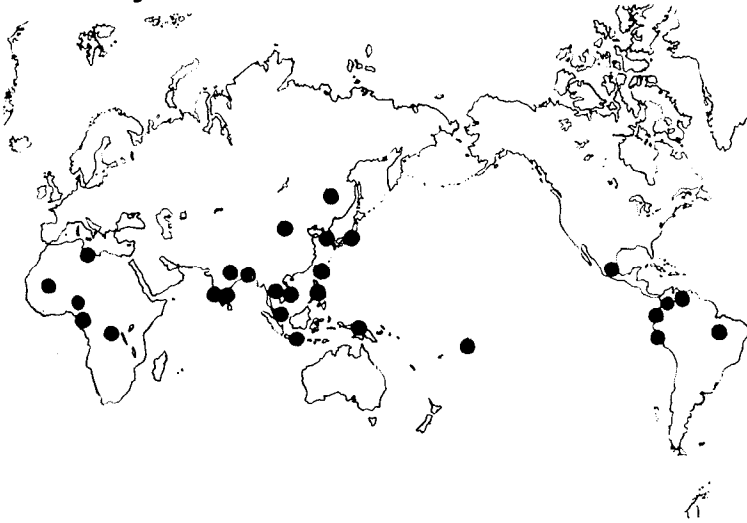


Fig.2. Key to the species of Paragonimus.

