

Presence of Epstein- Barr Virus in Oral Lichen Planus and Normal Oral Mucosa

**M Sahebamee¹, M Eslami², I Jahanzad³, M Babae¹, N Kharazani Tafreshi³*

¹ *Dept. of Oral Medicine, Faculty of Dentistry, Dental Research Center, Medical Sciences/ University of Tehran, Iran*

² *Dept. of Pathology, Faculty of Dentistry, Medical Sciences/ University of Tehran, Iran*

³ *Pouya Zistech Ltd., P.O. Box 16315- 769, Tehran, Iran*

(Received 5 Jul 2006; accepted 12 Feb 2007)

Abstract

Background: Oral lichen planus (OLP) is a chronic immunologic disease. The etiology of OLP is unknown, viral antigens (for example Epstein-Bar virus) have been proposed as etiologic agents. OLP may get transformation to malignancy so research on the presence of EBV in OLP lesions seems to be necessary. The aim of this study was to ascertain if EBV acted as etiologic factor in pathogenesis of OLP.

Methods: Tissue specimens of 22 patients with clinical diagnosis and histopathological confirmation of OLP were used as case group. And that of 22 persons without OLP served as control group. Polymerase Chain Reaction (PCR) method was used. Each sample was tested twice.

Results: All biopsy specimens from patients and controls were negative for EBV presence.

Conclusions: In spite of the fact that the presence of EBV in OLP in these two small groups of Iranian population was not confirmed with PCR method, but due to different ideas and reports in this field, proving or disproving of presence or etiological role of EBV in OLP is continuously a question and needs to be examined in further studies.

Keywords: *Oral lichen planus, Epstein- Barr virus, PCR, Iran*

Introduction

Oral lichen planus (OLP) is a chronic immunologic inflammatory disease with recovery and relapse periods and comes into existence by disorder in spinal layer of epithelium. Estimation the prevalence of OLP is difficult because of exact epidemiological studies deficiency and various symptoms and clinical features of this disease (1). Generally prevalence of OLP in different population has been reported 0.1-4% (2). Recent reports propound the role of immunological reactions in etiology of this disease but generally the etiology of OLP is unknown yet (3). The antigen responsible for inducing OLP is still unidentified, although viral agents have been proposed as etiologic factors (4). For example, Epstein-Barr virus (EBV) is associated with both malignant and benign diseases in the

head and neck region and OLP also shows malignant transformations sometimes (5-7), so we hypothesized that EBV maybe involved in the etiology of OLP.

The Epstein-Barr virus, a member of the human herpes virus group, is a double- stranded DNA virus widespread in the normal population. Approximately 90% of adults have demonstrable EBV antibodies. In-vivo, the infection is restricted to 2 target cells, the oronasopharyngeal or the salivary gland epithelium and B-cell lymphocytes (8). EBV has the ability to establish a latent infection, which means a silent state of viral infection, characterized by a low expression of viral genes and minimal cytopathic effects or production of infectious virus. EBV is associated with infectious mononucleosis and oral hairy leukoplakia (nonmalignant

disorders) (9-11) and with Burkitt lymphoma and nasopharyngeal carcinoma (NPC) (malignant disorders) (12-15). EBV has been demonstrated in normal oral epithelium as well as in oral squamous cell carcinoma (OSCC) (12, 16-18). Little is known about the state of EBV infection in epithelial carcinomas because of the lack of an appropriate in-vitro model (19), and the contribution of EBV to the development of malignancies is unclear (20).

Polymerase chain reaction (PCR) for in-vitro amplification of DNA has been used successfully for detection of EBV in the saliva of patients with NPC, B-cell lymphoma, and infectious mononucleosis (9). To take advantage of PCR sensitivity, we used it to examine the presence of EBV DNA in patients with OLP and control group.

Materials and Methods

Patients and clinical specimens Tissue specimens of 22 patients (2 men and 20 women; age, 26-78 yr) who had been referred to Oral Medicine Clinic in Faculty of Dentistry of Tehran University of Medical Sciences with clinical diagnosis and histopathological confirmation of OLP were used as case group. Biopsy specimens from clinically healthy oral mucosa of 22 persons (6 men and 16 women; age, 31-74 yr) without OLP who had been referred to Oral and Maxillofacial Surgery Clinic of the same university for various. Surgical operation such as 8th impacted tooth and residual root surgery, alveoloplasty, vestibuloplasty and apicoectomy served as control group.

Informed consent was obtained from all patients and control groups.

Tissue processing Local anesthesia (lidocaine 2%+ adrenaline 1/100,000; Darupakhsh, Tehran, Iran) was done to obtain biopsy specimens, which were taken from lesions in OLP patients and normal oral mucosa of control group. Immediately afterwards, the biopsy specimens were fixed in 10% neutral buffered formalin solution, embedded in paraffin and sectioned (7 µm).

DNA extraction 400 µl digestion buffer was added to 100-200 µl biopsy specimens containing virus (from OLP patients and control subjects) in 5/1 ml microtubes and mixed properly; 3-8 µl proteinase K solution was added, too. The obtained mixture was incubated 2 h at 37 °C. After incubation, 500 µl phenol- chloroform isoamyl alcohol solution was added to micro tube in the proportion of 1:24:25 (this solution causes protein sedimentation between organic and watery phases). After addition of phenol- chloroform isoamyl alcohol micro tube was shaken slowly for 5 min to mix the solution properly. Mixture was centrifuged in 12000 RPM at 4 °C for 15 min. With sampler watery solution was discharged and poured into another micro tube (if the solution was not transparent, this operation was repeated again); twice a volume of obtained mixture, pure ethanol alcohol and 0/1 volume of it, sodium- acetate three molar were added. After incubation at -20 °C for 12 h, the solution was centrifuged in 12000 RPM for 10 min then alcohol was discharged slowly and the sediment at the bottom of the tube was washed with alcohol 70%. (It means cold alcohol 70% was poured over sediment and centrifuged in 8000 RPM for 10 min). After centrifuging upper solution was discharged and the tube was left for alcohol evaporation. Obtained sediment was solved in 30 µl twice distilled sterile water and put at -20 °C for next stages. EBV (keyvan Viral Laboratory) viral isolates (that were obtained from Iranian patients) were used as positive controls.

PCR EBV PCR reactions consisting of 5 µl of extracted DNA was added to 20 µl PCR mix containing: 0/5 µm of each primers EBV-F, EBV-R, 1X PCR buffer, 1/5 mM mgcl₂, 0/2 mM dNTPs (deoxy ribonucleo side triphosphate), 2/5 U Taq DNA polymerase (Pouya Zistech, Iran) of PCR assay was performed. PCR was carried out using the following programs: 94 °C for 3 min (Predenaturation), 35 cycles at 94 °C for 30 s, 55 °C for 30 s, 72 °C for 30 s, with a final extension at 72 °C for 5 min. To monitor the pres-

ence of inhibitors, β_2 - micro globulin primers (F: GGTGTCTTGAGGCTCAGGGAG, R: CAACTTCAATGTCGGATGGATG) were included in each test sample as internal control. DNA extraction was repeated when samples in PCR were not positive for β_2 -microglobulin gene. Also a control containing all reagents of PCR except DNA was used as negative controls.

Gel electrophoresis Electrophoretic separation of products was performed on a 1/5% agarose gel (Gibco BRL, Germany) in 1XTBE buffer (Tris borate) pH 8/0. Agarose gels were stained

with ethidium bromide, bands visualized under UV- light and photographed for documentation.

Results

The size of PCR products using EBV-F, EBV-R primers was 180 bp and the size of PCR products of internal control (by β_2 - micro globulin primers) was 250 bp. [The primers was used as described by manufacturers (Pouya Zistech, Iran)]. All OLP and control specimens were positive for β_2 - micro globulin and thus included in the study and all of them were negative for EBV presence. (Fig. 1, 2).

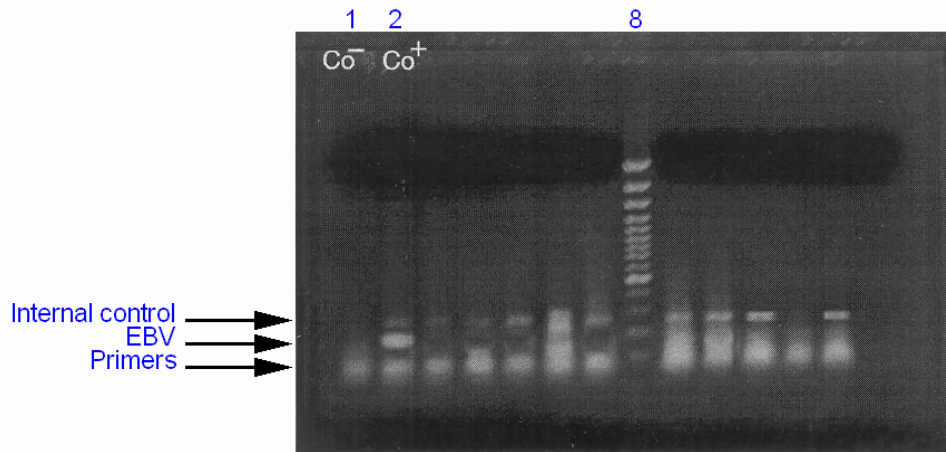


Fig 1.

Internal: 250 bp
EBV: 180 bp

Fig. 1: Detection of EBV in OLP on a 1/5% agarose gel after electrophoresis and staining with ethidium bormide. PCR was made and the PCR product is 180 base pair (bp). Lane 1 shows the negative control. Lane 2 shows the postitive control. Lane 8 shows a molecular size marker. Other lanes show negative cases.

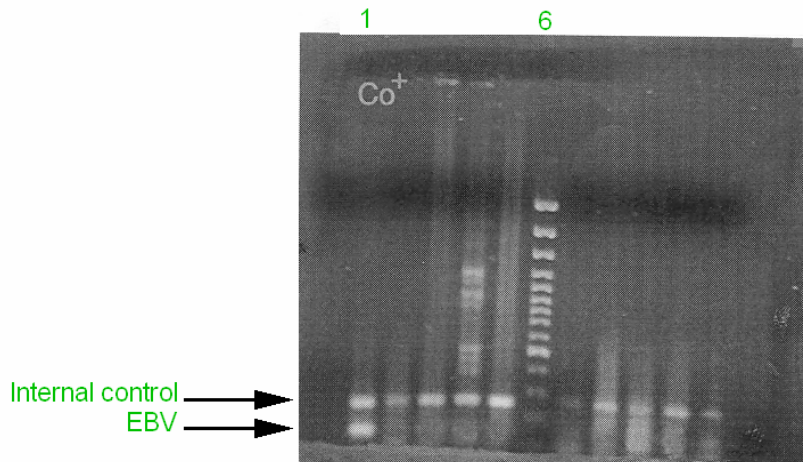


Fig. 2: Lane 1 shows the positive control. Lane 6 shows a molecular size marker. Other lanes show the negative cases. (Photography of continuation of electrophoresis).

Discussion

The association between EBV and premalignant and malignant disorders has been studied for the oral region. Some authors consider OLP to be premalignant lesions, but the premalignant potential of OLP remains controversial (5, 21, 22). Regarding the possible premalignant potential of OLP, earlier investigators have reported a correlation between degree of dysplasia in leukoplakias and EBV prevalence (16, 23, 24). In any cases, the premalignant potential of OLP can not be ruled out.

Pedersen (4) observed specific EBV DNA in some OLP specimens and suggested that EBV maybe involved in the pathogenesis of some oral lesions. In another study, investigators found 26/1% EBV positivity in OLP as compared with 7/3% in control subjects (25). But whether the EBV infection is involved in the pathogenesis of OLP, or whether the EBV infection is secondary to the OLP lesions as a result of a possible local immunosuppression, is difficult to say.

In our study, we used PCR method and have failed to detect any difference in EBV prevalence between OLP and control subjects. Other investigators using PCR have failed to detect any difference in OSCC and control subjects (26-28), too, and the EBV prevalence differs from 0% to 100% in previous studies of OSCC with PCR (23,26-33). In another study, PCR method was employed to detect members of the human herpes virus (HHV) in 38 OLP specimens and 20 normal control buccal mucosa tissue samples. EBV was detected in small percentages of tissue samples, therefore, this result not suggest a causative role for members of HHV family in the pathogenesis of OLP (34). In similar study, PCR was carried out in 10 specimens of oral erosive lichen planus (ELP) and 5 specimens of normal oral mucosa. No EBV was demonstrated in ELP patients' and control subjects' specimens (35). Although the numbers of patients in our research are more

than theirs but the results are the same. This similarity in results may be due to common social behaviors in Asian countries, because that research has been also carried out in Asian population (Taiwan).

These high variability and inconsistency probably reflect geographical difference as well as differences in methodological sensitivity (25).

EBV prevalence in clinically healthy oral mucosa was reported 7/3% (25). Earlier studies on EBV prevalence in normal oral mucosa showed different results which apparently depended on methods of sample collection. Oral smears, scrapings and throat washings seem to give a higher EBV prevalence, with 20% to 90% EBV positivity in adults (16, 36-38).

For oral smears, scrapings and throat washings, EBV DNA was possibly present in contaminating saliva, which would explain the high EBV prevalence in a normal population when such collection methods are used. However, Mao and Smith (16) found indications that oral exfoliated cells can be positive for EBV DNA when saliva samples are negative.

High EBV prevalence in OLP in some studies (4, 25) might be due to a decrease in the immune defense, locally or generally. Studies on immune-compromised patients seem to support this theory, because they show a higher prevalence of EBV, even in clinically normal oral mucosa (39). Accordingly, EBV was not found in 30 normal tongue samples of immunocompetent individuals (40). We didn't detect any EBVDNA in our control subjects, therefore, EBV presence in healthy oral mucosa in Iranians is negative, and consequently, this result is nearly equal to the results of investigators that couldn't have obtained any EBV positivity in normal oral mucosa in their researches.

In one research (25), investigators reported presence of EBVDNA in clinically healthy oral mucosa and OLP lesions in their studied population. This shows that EBV could be one of the

normal flora component of their mouth and higher prevalence of EBV in their country.

Three theories for the presence of EBV DNA in oral premalignant and malignant lesions have proposed by Horiuchi et al. (24): [i] EBV infection may be involved in the carcinogenesis of oral squamous cell epithelium; [ii] EBV easily infects squamous cell carcinoma cells [iii] EBV exists in cancer cells as a passenger.

Our investigation showed no EBV positivity in OLP and control subjects but this result cannot reject role of EBV in oral lesions such as OLP, therefore, further studies need to be done for definitive conclusions.

Acknowledgements

This research was supported by a grant from Dental Research Center, Tehran University of Medical Sciences, Tehran, Iran.

References

1. Greenberg C (2003). *Burket's Oral Medicine Diagnosis and Treatment*. 10th ed. BC Decker, Spain, pp: 107-10.
2. Scully C, Beyl M, Ferreiro M, Ficarra G, Gill Y, Giffiths M (1998). Update on oral lichen planus, etiopathogenesis and management. *Crit Rev Oral Biol Med*, 9(1): 86-107.
3. Regezi J, Scubba J, Jordan CK (2003). *Oral pathology*. 4th ed. W.B Saunders, Philadelphia, pp: 92-3.
4. Pedersen A (1996). Abnormal EBV immune status in oral lichen planus. *Oral Dis*, 2(2): 125-8.
5. Markopoulos AK, Antoniadis D, Papanayotou P, Trigonidis G (1997). Malignant potential of oral lichen planus; a follow-up study 326 patients. *Oral Oncol*, 33(4): 263-69.
6. Rajentheran R, Mclean NR, Kelly CG, Reed MF, Nolan A (1999). Malignant transformation of oral lichen planus. *Eur J Surg Oncol*, 25(5): 520-23.
7. Mignogna MD, Lo Muziol, Lo Russol, Fedele S, Ruoppo E, Bucci (2001). Clinical guidelines in early detection of oral squamous cell carcinoma arising in Oral lichen planus: a 5-year experience. *Oral Oncol*, 37(3): 262-67.
8. Syrjänen S (1992). Viral infections in oral mucosa. *Scand J Dent Res*, 100(1): 17-31.
9. Saito I, Nishimura S, Kudo I, Fox R, Moro I (1991). Detection of Epstein-Barr virus and human herpes virus type 6 in saliva from patients with lymphoproliferative diseases by polymerase chain reaction. *Arch Oral Biol*, 36 (2): 779-84.
10. Banks P (1967). Infectious mononucleosis: a problem of differential diagnosis to the oral surgeon. *Br J Oral Surg*, 4(4): 227-34.
11. Greenspan J, Greenspan D, Lennette E (1985). Replication of Epstein-Barr virus within the epithelial cells or oral "hairy" leukoplakia, and AIDS-associated lesion. *N Engl J Med*, 313(6): 1564-71.
12. Hausen H, Schulte-Holthausen H, Klein G (1970). EBV DNA in biopsies of Burkitt tumors and anaplastic carcinomas of the nasopharynx. *Nature*, 228(2):1056-58.
13. Shope T, Dechairo D, Miller G (1973). Malignant lymphoma in cottontop marmosets after inoculation with Epstein-Barr virus. *Proc Natl Acad Sci*, 70(4): 2487-91.
14. Dawson C, Richinson A, Young L (1990). Epstein-Barrvirus latent membrane protein inhibits human epithelial cell differentiation. *Nature*, 344(4): 777-80.
15. Wolf H, Hausen H, Becker V(1973). EB viral genomes in epithelial nasopharyngeal carcinoma cells. *Nature-new Biology*, 244(3): 245-47.
16. Mao E, Smith C (1993). Detection of Epstein Barr virus (EBV) DNA by the polymerase chain reaction (PCR) in oral smears from healthy individuals and patients with squamous cell carcinoma. *J Oral Pathol Med*, 22(1):12-7.

17. Feinmesser R, Miyazaki I, Cheung R, Freeman J, Noyek A, Dosch H-M (1992). Diagnosis of nasopharyngeal carcinoma by DNA amplification of tissue obtained by fine-needle aspiration *N Engl J Med*, 326(1): 17-21.
18. Hausen H, Schulte-Holthausen H, Klein G (1970). EBV DNA in biopsies of Burkitt tumours and anaplastic carcinomas of the nasopharynx. *Nature*, 228(4): 1056-8.
19. Boulter A, Johnson N, Birnbaum W, Teo C (1996). Epstein-Barr Virus (EBV) associated lesions of the head and neck. *Oral Dis*, 2(2):117-24.
20. Dufva M (2001). Functional aspects on the Epstein-Barr Virus nuclear antigen 5. Institute of laboratory Medicine, Department of clinical chemistry and Transfusion Medicine. Göteborg: Göteborg University; Available from: www.google.com
21. Meij EVd, Schepman k, Smeele L, Waal Jvd, Bezemer P, waal Ivd (1999). A review of the literature regarding malignant transformation of oral lichen planus. *Oral Surg Oral Med Oral Pathol Oral Radiol Endod*, 88(4): 307-10.
22. Lozada-Nur F, Miranda C (1997). Oral lichen planus: epidemiology, clinical characteristics, and associated diseases. *Semin Cutan Med Surg*, 16(3): 273-7.
23. D' Costa J, Saranath D, Sanghvi V, Mehta A (1998). Epstein-Barr virus in tobacco-induced oral cancers and oral lesions in patients from India. *J Oral Pathol Med*, 27(1): 78-82.
24. Horiuchi K, Mishima K, Ichijima KK, Sugimura M, Ishida T, Kirita T(1995). Epstein-Barr Virus in the proliferative diseases of squamous epithelium in the Oral cavity. *Oral Surg Oral Med Oral Pathol Oral Radiol Endod*, 79(1): 57-63.
25. Sand Lp, Jalouli J, Larsson per-A, Hirsch Jan M (2002). Prevalence of Epstein-Barr Virus in oral squamous cell carcinoma, oral lichen planus, and normal oral mucosa. *Oral Surg Oral Med Oral Pathol Oral Radiol Endod*, 93(6): 586-92.
26. Heerden W, Rensburg E, Engelbrecht S, Raubenheimer E (1995). Prevalence of EBV in oral squamous cell carcinomas in young patients. *Anticancer Res*, 15(2): 2335-40.
27. Rensburg E, Engelbrecht S, Heerden W, Raubenheimer E, Schoub B (1995). Detection of EBV DNA in oral squamous cell carcinomas in a black African population sample. *In Vivo*, 9(2): 199-202.
28. Mizugaki Y, Sugawara Y, Shinozaki F, Takada K (1998). Detection of Epstein-Barr Virus in oral papilloma. *Jpn J Cancer Res*, 89(6):604-7.
29. Tshako K, Nakazato I, Miagi J (2000). Comparative study of oral squamous cell carcinoma in Okinawa, Southern Japan and Sapporo in Hokkaido, Northern Japan: with special reference to human papilloma Virus and Epstein-BarrVirus infection. *J Oral Pathol Med*, 29(1): 70-9.
30. Cruz I, Brule AV, Steenbergen R (1997). Prevalence of Epstein-Barr Virus in oral squamous cell carcinomas, premalignant lesions and normal mucosa: a study using polymerase chain reaction. *Oral Oncol*, 33(2): 182-8.
31. Maeda T, Hiranuma H, Matsumura S, Furukawa S, Fuchihta H (1998). Epstein-Barr Virus infection and response to radiotherapy in squamous cell carcinoma of the oral cavity. *Cancer Lett*, 125(1): 25-30.
32. Gonzalez- Moles M, Guitierrez J, Ruiz I, Fernandez J, Rodriguez M, Aneiros J (1998). Epstein-Barr virus and oral squamous cell carcinoma in patients without HIV infection: Viral detection by polymerase chain reaction. *Microbios*, 96: 23-31.
33. Kobayashi I, Shima K, Saito I (1999). Prevalence of Epstein-Barr Virus in oral

- squamous cell carcinoma. *J Pathol*, 189(1): 34-9.
34. OFlatharta C, Flint SR, Toner M, Butler D, Mabruk MJ(2003). Investigation into a possible association between oral lichen planus, the human herpesviruses, and the human papilloma viruses. *Mol Diagn*, 7(2): 73-83.
35. Sun A, Chang JG, Chu CT, Liu BY, Yuan JH, Chiang CP (1998). Preliminary evidence for an association of Epstein-Barr Virus with pre-ulcerative oral lesions in patients with recurrent aphthous ulcers or Behcet's disease. *J Oral Pathol Med*, 27(4): 168-75.
36. Voog E, Ricksten A, Olofson S (1997). Demonstration of Epstein-Barr Virus DNA and human papillomavirus DNA in acetiwhite lesions of the penile skin and the oral mucosa. *Int J STD AIDS*, 8(8): 772-75.
37. Scully C, Porter S, Alberti L, Jalal M, Maitland N (1998). Detection of Epstein-Barr Virus in oral scrapes in HIV infection, in hairy leukoplakia, and in healthy non-HIV-infected people. *J Oral Pathol Med*, 27(5): 480-82.
38. Ikuta K, Satoh Y, Hoshikawa Y, Sairenji T (2000). Detection of Epstein-Barr Virus in salivas and throat washings in healthy adults and children. *Microbes Infec*, (2)2: 115-20.
39. Alder-Storthz K, Ficarra G, Woods K, Gaglioti D, DePietro M, Shillitoe E (1992). Prevalence of Epstein-Barr Virus and human papilloma Virus in oral mucosa of HIV- infected patients. *J Oral Pathol Med*, 21(2): 164-70.
40. Miller D, Heard P, Cagle M (1994). Absence of reservoir of Epstein-Barr Virus (EBV) in normal tongue epithelium. *J Oral Pathol Med*, 23(2): 156-60.