

# Fish Anisakidae Helminthes in KHuzestan Province, South West of Iran

<sup>1</sup>A Farahnak\*, <sup>1</sup>I Mobedi, <sup>2</sup>R Tabibi

<sup>1</sup>Department of Parasitology and Mycology, School of Public Health, Tehran University of Medical Sciences, Tehran, Iran.

<sup>2</sup>Ahwaz Health Center, Ahwaz University of Medical Sciences, Ahwaz, Iran

---

---

## ABSTRACT

Fish including; *Barbus* spp, *Cyprinus carpio*, *Liza abu* and *Aspius vorax* have very important role in the economic condition of the rural areas of Khuzestan province. These fish have been consumed as fried or roasted. Inadequately cooked fish, could be served as a source of infection in these communities. For this reasons, 701 fish were trapped from 4 lagoons (Atash, Sobhanieh, Al-hai, Houfel) and transported alive to Ahwaz Health Research Center. Their skin, gills, eyes, muscles, intestine and body cavity were examined carefully. In 54 (7.7%) of fish, 6 cases of *Contracaecum* sp. (0.85%) and 48 *Anisakis* sp. (6.8%) were identified belong to helminth family of anisakidae. These results suggested that human anisakiasis could be health hazard in these areas.

**Key words:** Anisakidae, Fish, Iran

---

---

## INTRODUCTION:

*Anisakis simplex* is a common nematode parasite present in many marine fish, including finfish and squid. It is potentially a public health problem if is not destroyed during food processing (4). *Anisakis simplex* can cause different diseases in humans. The human acquire the larvae by eating raw or undercooked seafoods. Acute anisakidosis is probably caused by an inflammatory and/or allergic response in the digestive tract mucosa with abdominal pain. It can also induce IgE-mediated reactions with several clinical manifestations ranging from urticaria and angioedema to anaphylaxis. Chronic anisakidosis results from abscesses or eosinophilic granulomas caused by parasite invasion (2).

Fish are the main meal of the people of khuzestan province in south west of iran. Fresh fish are consumed as fried or roasted especially in the rural areas. The Lagoons, which are the most important fisheries resources, have very important ecological effects on fish parasites. There are many records of *Contracaecum spp* and *Anisakis sp.* from fish in the Caspian Sea and Persian Gulf (1, 3) but anisakidae infection has been poorly described from host in the lagoons (5).

This study is a part of a research project entitled "The faunistic survey on fish helminthes in south west of Iran". The purpose of the present study was to determine the anisakidae infection in fish.

## MATERIALS and METHODS

The 4 lagoons including Atash, Sobhanieh, Al-hai and Houfel in the central area of khuzestan province, south west of Iran were surveyed. In this respect, 701 fish from 5 species including; *Barbus grypus* (shirbot), *B. lateus* (hemri), *Cyprinus carpio* (kapour), *Liza abu* (biah), and *Aspius vorax* (sheleg), were caught by the local fishermen and transported alive to the laboratory of Ahwaz Health Research Center from 1998 to 2000.

Fish were dissected and skin, gills, eyes, muscles, intestine and body cavity were observed carefully and nematodes were collected then fixed in 70% ethanol or 10% formaldehyde and cleared in lactophenol or stained with azocarmin. Drawings were made with aid of a leica microscope drawing attachment (camera lucida) and identification was conducted using valuable references (7).

## RESULTS

From the total fish examined in this survey, intestinal tract of 54 (7.7%) fish contained nematodes of either *Contracaecum* sp. (fig.1) or *Anisakis* sp. (fig.2). The results of prevalence of helminth parasites from 701 fish surveyed are given in Table1. The study of fish from lagoons in khuzestan province has been shown a high rate of infection (7.7%) with Anisakidae larvae which could be a health hazard for people in this area once provided to be eaten raw or undercooked. Relative frequencies of caught fish according to the sex, length and

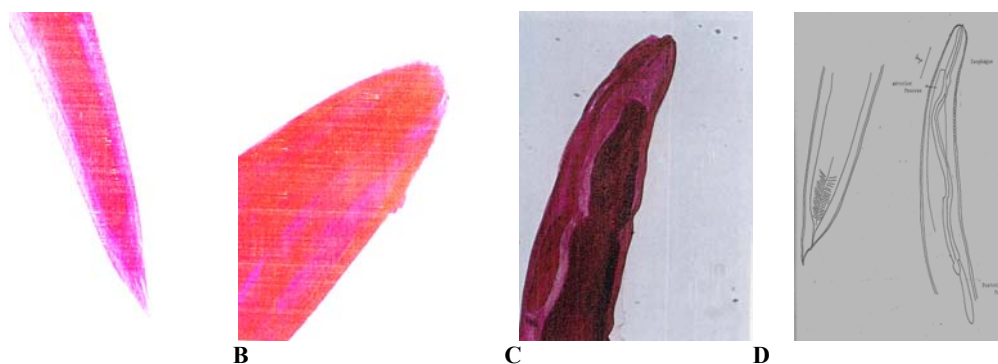
---

\*Correspondence author: P.O.Box: 14155-6446. farahnak @ sina.tums.ac.ir

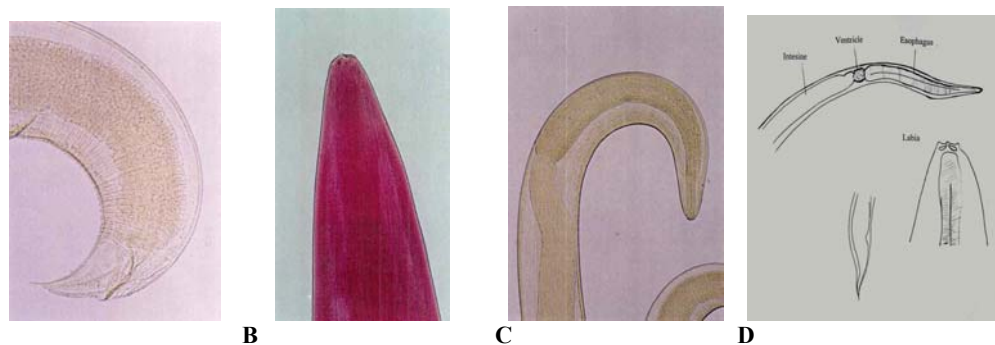
weight are shown in fig. 3. Majority of caught fish were with length of 100-149 mm and weight to less 50g.

**Table 1 . Prevalence of Anisakidae Helminth Parasites From 701 fish surveyed in South West of Iran.**

Fish species	<i>Contracaecum</i> sp.	<i>Anisakis</i> sp.
<i>B. grypus</i> ( Shirbot )	1	1
<i>B. luteus</i> ( Hemri )	0	2
<i>A. vorax</i> ( Sheleg )	4	7
<i>C. carpio</i> ( Kapour )	1	33
<i>L. abu</i> ( Biah )	0	5
Total of infected fish	6	48
Percent of infected fish ( from 701 fish )	0.85%	6.84%



**Fig. 1. Anisakidae helminth parasites from surveyed fish in south west of Iran: *Contracaecum* sp. Caudal end (A), Head (B), Anterior end(C), Drawing picture (D)**



**Fig. 2. Anisakidae helminth parasites from surveyed fish in south west of Iran: *Anisakis* sp. Caudal end (A), Head (B), Anterior end(C), Drawing picture (D)**

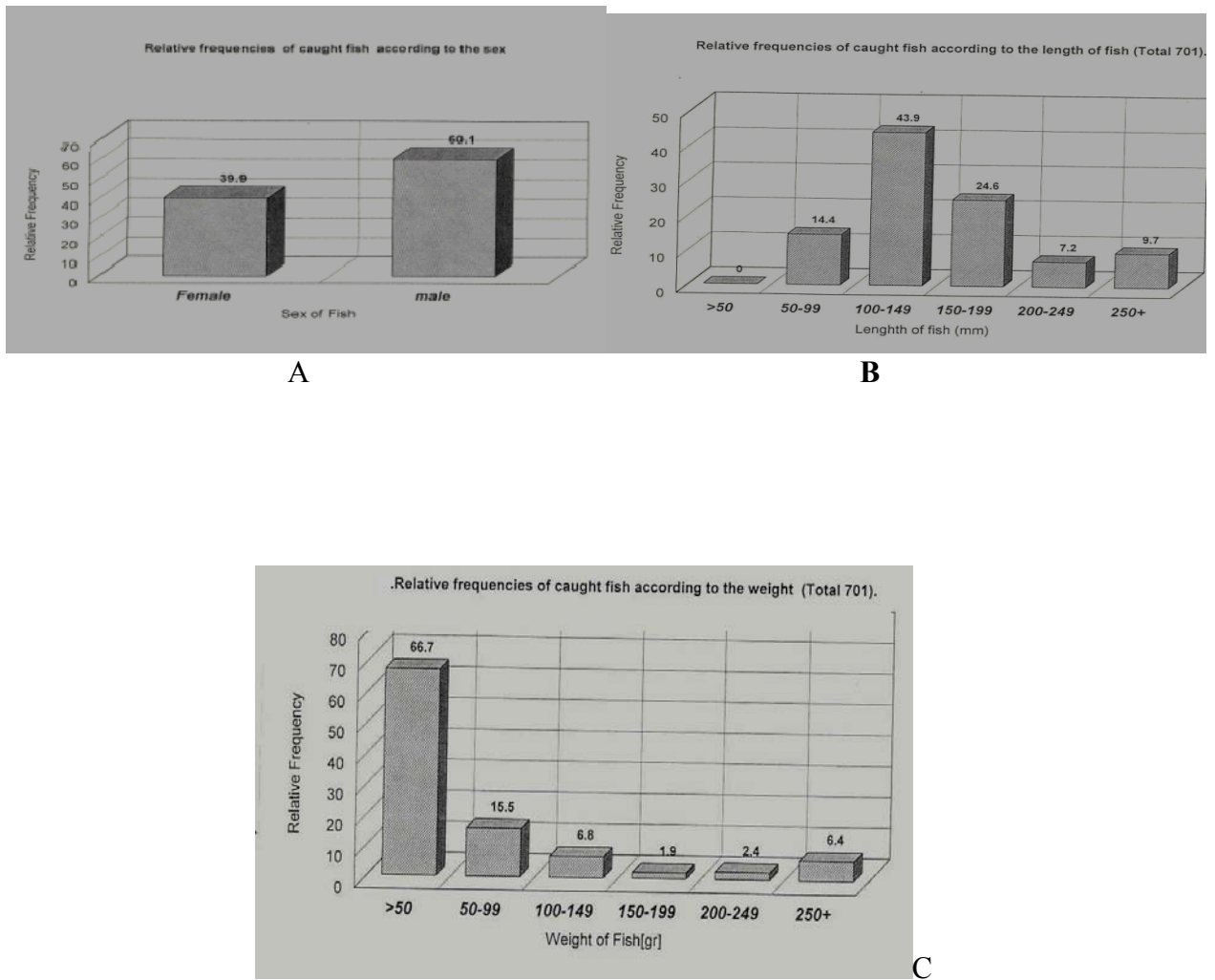


Fig. 3. Anisakidae helminth parasites from surveyed fish in south west of Iran: Relative frequencies of caught fish according to sex (A), length (B) and weight(C).

### Discussion

From an ecological point an important question is; what's the origin of fish anisakidae in this region? May be there are two answers for this question. First, the lagoons are refuges of migratory birds, which could be host of anisakidae parasite. Recently we found an *Anisakis sp.* parasite from the birds (unpublished data). Second, the Atash (Shadegan) lagoon is near the Persian Gulf (the seawater) and is connected with it. The Persian Gulf could contain host of parasites.

Fish treatment at a pressure of 200 MPa for 10 min at a temperature between 0 and 15 degree C, kills all *Anisakis* larvae, with a lack of motility being used as an indicator of larval death (4). As preventive measures heating for 10 min over 65 °C or freezing (minus 20 °C for 24 h) destroys the infectivity of the larval stage but not always prevent allergic reactions(2). The endoscopic extraction of possible larvae is the only effective therapy, as anthelmintics against

nematodes (mebendazole, albendazole, and thiabendazole) are ineffective (6).

### ACKNOWLEDGMENTS

I thank the staff of Ahwaz Health Research Center for providing specimens especially M. Saffar, M. Siavashpoury, M. Foladvand and F. Kasiri. Thanks are also to Professor Baluch for fish species diagnosis and research affaire of school of Public Health & Health Research Institute, Tehran University of Medical Sciences for support.

### REFERENCES

1. Eslami A, Anwar M and Khatibi S (1972). Incidence and intensity of helminthiasis in pikes

- (*Esox lucius*) of Caspian Sea. *Riv. It. Piscic. Ittiop.* 7 (1): 445-8.
2. Gani F, Lombardi C, Senna G, Mezzelani P (2001). Anisakiasis: a borderline disorder. *Recenti Prog. Med.* 92 (4): 605-6.
  3. Mokhayer B (1974). Pseudotongue in snapper fish of Persian Gulf. *proc.3th. Int. cong. parastol. Monchen*345-8
  4. Molina-Garcia AD, Sanz PD (2002). *Anisakis simplex* larva killed by high-hydrostatic-pressure processing. *J Food Prot.* 65 (2): 383-8.
  5. Pazoki J (1996). A faunistical survey and histopathological studies on freshwater fish nematodes in Iran and Hungary. Ph.D thesis. *Vet. Med. Res. In. Hun Acad. of Sciences, Hungry*Plath.
  6. Plath F, Holle A, Zende D, Moller FW, Barten M, Reisinger EC, Liebe S (2001). Anisakiasis of the stomach--a case report from Germany. *Z. Gastroenterol.*39(2): 177-180.
  7. Pavlovskii E.N (1964). Key to parasites of freshwater fish of the U.S.S.R. Translated from Russian. 616 spp. Israel program for scientific translations, Jerusalem.