

## ***Enterobius vermicularis*: A Controversial Cause of Appendicitis**

**\*Gh Mowlavi<sup>1</sup>, J Massoud<sup>1</sup>, I Mobedi<sup>1</sup>, M Rezaian<sup>1</sup>, S Solaymani Mohammadi<sup>1</sup>,  
NE Mostoufi<sup>2</sup>, MJ Gharaguzlo<sup>3</sup>**

<sup>1</sup>*Dept. of Medical Parasitology, School of Public Health, Tehran University of Medical Sciences, Iran*

<sup>2</sup>*Dept. of Pathology, Faculty of Medicine, Ahvaz University of Medical Sciences, Iran*

<sup>3</sup>*Dept. of Pathology, Faculty of Veterinary, Tehran University, Iran*

---

### **Abstract**

Enterobiasis is undoubtedly one of the most common human helminths infections through the world, with an estimate of 1000 million cases worldwide. Although adult worms and their eggs are frequently found in inflamed appendices, but the role of the parasite in producing appendicitis in humans still remains controversial. Although acute appendicitis may occur at any age, but it is relatively rare at the extremes of age. A histopathological study of infested appendices with *Enterobius vermicularis* was performed in Khuzestan province, south western Iran, during 2001 to 2003. All 40 samples had surgically been removed during the emergency operations and histopathological process with (H&E) staining has been performed for each. One of the main objects of this work was to collect more data about the possible role of this highly prevalent human round worm as a causative agent of appendicitis in humans, leading to different types of appendicitis in this part of the country. In this occasion over the slide examinations of the tissue sections, fewer cases than expected, with worm infested appendices were seen exclusively affected with this parasite.

**Keywords:** *Appendicitis, Enterobius vermicularis, Histopathology, Iran*

---

### **Introduction**

*Enterobius vermicularis* (L, 1758, Leach, 1853) is a cosmopolitan parasite of humans residing in the lumen of the ceacum and appendix, and the most common parasitic helminths of humans in temperate, developed countries. It infects 1000 million cases worldwide in particular in temperate and cool climates (1). In colder climates, some factors such as less exposure to sun light, heavy clothing and fewer baths lead to higher prevalence of enterobiasis, especially in children. It generally inhabits the large intestine but is of low pathogenicity. Occasionally, however, ova can be found in ectopic sites in the peritoneal cavity and sometimes in the appendix (2). Despite its high prevalence, enterobiasis is not usually considered to be a serious disease, although ectopic infections seem most commonly in females, can cause signifi-

cant morbidity (3). Another possible complications of enterobiasis must be taken into account when this tiny round worm crawls itself to the lumen of the appendix leading to appear some clinical manifestations resemble to acute appendicitis that are still in challenge throughout the papers. Appendicitis is the most common acute surgical condition of the abdomen. Approximately 7 percent of the population will have appendicitis in their life time, with the peak incidence occurring between the age of 10 and 30 years (4). Approximately 250,000 cases of appendicitis occurred annually in the United States during the years of 1979-1984, accounting to an estimated 1 million hospital days per year (5). Although the exact data on appendicitis is not well-organized throughout the country, but in Iran however, the rate of emergency operations linked to appendicitis could be significantly in attention. Obstruction of the nar-

row appendiceal lumen initiates the clinical illness of acute appendicitis. Obstruction has multiple causes, including lymphoid hyperplasia (related to viral illnesses, including upper respiratory infection, mononucleosis, and gastroenteritis), fecaliths, parasites, foreign bodies, Crohn's disease, primary or metastasis cancer and carcinoid syndrome (6, 7). Several authors have looked at the relationship of pinworm infestation and appendicitis. Studies carried out in England have demonstrated a prevalence of pinworm appendicitis from 1.5% to 4.2% in specimens removed for presumptive acute appendicitis (8).

The histological findings revealed, however, that the pin worms were most commonly seen in association with chronic inflammatory changes and not with acute inflammation. Other histological characteristics include prominent eosinophilia and granulomatous inflammation which must be distinguished from chronic changes seen in inflammatory bowel disease. Occasionally, worms lodge in ectopic sites, such as the fallopian tubes or the ovaries and in peritoneal granulomatous nodules (9). It is also well accepted that, one of the possible causes of "acute abdomen" in children may be parasitic infections. *E. vermicularis* is the most common parasite occurring in man infecting about 10% of population in developed countries, the infection rate in children is even higher (10). In parallel with our common understanding to the possible role of human pinworms in acute or other types of appendicitis, recent large-scale examinations have not supported an association between *E. vermicularis* or any other helminths and appendicitis (9). So the incidence of appendectomy, appendicitis and enterobiasis in a same group of age has directed the interests of the authors to begin this work as a part of comprehensive research in future.

## Materials and Methods

During the 15 month period between July 2001 and September 2003, 40 appendiceal specimens

(25 already prepared paraffinized blocks, and 15 actively received tissue materials) were performed in Ahwaz Health Research Station affiliated to the School of Public Health and Institute of Public Health Research, Tehran University of Medical Sciences, Iran. All the samples were belonging to the patients who had been operated in emergency surgical units in different hospitals of Khuzestan province, for which *E. vermicularis* infestation had histopathologically been diagnosed postoperatively. The tissues which were not embedded in paraffin were processed in tissue processor and uniformed in blocks of paraffin for being ready to cut by microtome. Five micrometer sections of the slides were kept in an oven at 65 °C for 20 min for being the sections flatten and fixed onto the surface of the slides. Before hydration, the slides were immersed in xylenes for 20 s, and then placed in decreasing concentrations of ethanol (100%, 96% then 70%) for approximately 10-15 s each. The tissue sections were Haematoxylin and Eosin stained for 15 and 2 min, respectively. After immersing the stained slides in increasing concentrations of ethanol (70%, 80%, 96%, and 100%), for 10 s each, and in xylene for 2 min the slides were mounted in entalen-61.

The prepared histological slides were studied under the different magnification of light microscopy and histopathological observations of the specimens were interpreted individually for each.

## Results

To understand the role of *E. vermicularis* in the pathogenesis of appendicitis, authors studied the results of the tissue sections of 40 appendiceal material during 15-months in the laboratory of Ahwaz Health Research Station and Department of Medical Parasitology and Mycology in Tehran. Sex and age distribution of the patients studied in this work are categorized in Table 1. The main histopathological changes observed in all 40 appendices surgical removed

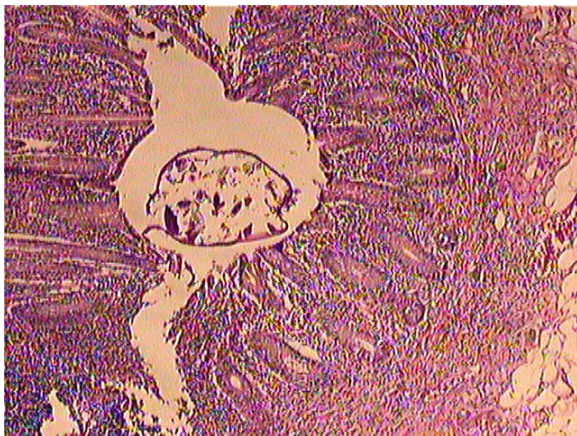
during an emergency operation are listed in Table 2. In most of the slides, at least one or two cross sections of *E.vermicularis* were easily detected (Fig. 1). In some cases, presence of the worm sections surrounded in fecaliths (Fig. 2) with a number of eggs (Fig.3) inside their uteruses, were strongly supporting the diagnosis for enterobiasis appendicitis.

**Table 1:** Age group and gender of the patients

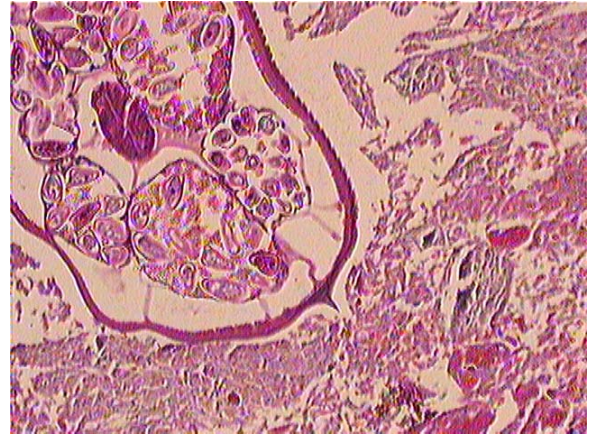
Age group(Years)	Male		Female		Total	
	No	%	No	%	No	%
9-11	8	4.44	10	55.5	18	45
20-29	7	6.46	8	53.3	15	37.5
>30	3	50	3	50	6	15
Total	8	45	21	52.5	39	97.5

**Table 2:** Different histopathological signs seen in appendiceal samples

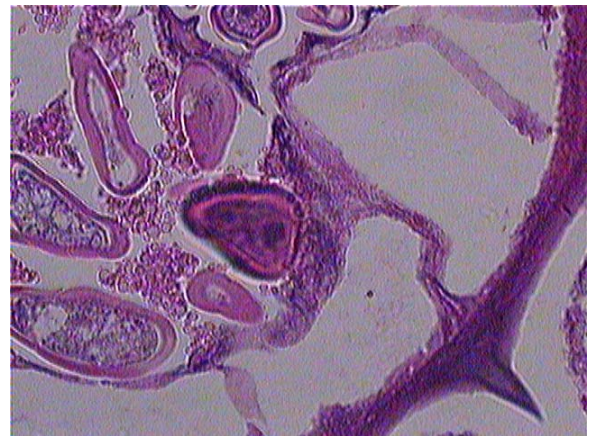
Histopathological signs	Number	%
Cross sections of <i>E.vermicularis</i>	40	100
Eggs in the lumen	1	4
Purulent exudates	20	50
Fecaliths	18	45
Infiltration of neutrophils	23	57.5
Necrosis of the wall	2	5
Perforation	-	-
Mucosal microabscesses	3	7.5
Tissue eosinophilia	8	20
Obstruction	5	12.5
Granulomatous inflammation	8	20



**Fig. 1:** Cross section of *E.vermicularis* in the lumen of appendix X4



**Fig. 2:** Fecaliths in the lumen x10



**Fig. 3:** Eggs in the uterus of the worm x40

## Discussion

The relationship of pinworm infection to acute appendicitis has not been demonstrated, although *E. vermicularis* has been found in many patients with symptoms of appendicitis and where no other cause has been found (9). However, in a variety of studies carried out in different parts of the world, the parasite has been found in removed appendices (11-13). For example, in one study done in Venezuela, 3500 surgically-removed appendices were examined and *E. vermicularis* was found in 11% of the cases (12).

Histopathologically, increased eosinophils, focal eosinophilic microabscesses, purulent exudates, and granulomatous inflammation are the most frequent findings seen in most cases. The histological findings revealed, however, that the pinworms are most commonly seen in associa-

tion with chronic inflammatory changes and not with acute inflammation. In the present study, neutrophil infiltration (57.5%), purulent exudates (50%), fecalithis (45%), and granulomatous inflammation (20%) were the most frequent histologic findings observed. In a similar study in Hamadan province, western Iran, the reactive follicular hyperplasia and purulent acute appendicitis were the most observed pathologic findings (14). It seems that *E. vermicularis* causes the reactive follicular hyperplasia in most cases, and this is why the roundworm just causes obstruction and producing abdominal pains. Although the results in the present study are fully in agreement with previous findings in Iran, but through these manifestations we had, enterobiasis could not necessarily be claimed as the causative agent of acute appendicitis. Although pinworms are usually considered to be asymptomatic inhabitants of the intestine, when they do cause symptoms there can be a spectrum of non-specific gastrointestinal complaints. It has been proposed that possibly *E. vermicularis* is the cause of appendicitis-like symptoms (pseudo-appendicitis) or, on the other hand, worms may leave an appendix that is inflamed (5). However, the clinical signs in the patients below 6-year old are uncertain making them difficult to interpret. In some cases, even the sophisticated diagnostic methods may be insufficient to apply in infection diagnosis.

The results of the present study, showed that *E. vermicularis* was likely to be involved partly in the etiology of appendicitis in young children. The authors concluded that the presence of the parasite in the appendix can cause symptoms in some way similar to those found in acute appendicitis. Finally, it is drawn from the results that the presence of *E. vermicularis* in a case of acute appendicitis may be incidental. As seen in the previous studies, the parasite can cause chronic inflammatory responses in appendices infected, and should be taken into account in persons with a history of recent infection, especially in children.

Proper control strategies and complete treatment of infected children may influence the incidence of appendicitis where no other causes are found.

### Acknowledgments

We would like to thank Miss F Kasiri, Mr A Siavashpouri, from Ahwaz Health Research Station, for sample collection. We also thank the friendly cooperation of Mr A Rahimi, Miss Sh Jafarian and Neda Mirsepahi for their kind assistance in all Steps of the research.

### Reference

1. Cook GC (1994). *Enterobius vermicularis* infection. *Gut*, 35: 1159-62.
2. Listoro G, Ferranti F, Mancini G et al (1996). The role of *Enterobius vermicularis* in etiopathogenesis of appendicitis. *Minerva chir*, 51: 293-96.
3. Russell LJ (1991). The pinworm, *Enterobius vermicularis*. *Prim care*, 18: 13-24.
4. Haren DM (1999). Acute appendicitis: Review and update. *American family Physician*, November 1 (Especial print).
5. Addiss DG, Shaffer N, Fowler BX, Tauxe TV (1986). The epidemiology of appendicitis and appendectomy in the United State. *Am J Epidemiol*, 132:5-910.
6. McFadden LC (1997). Acute abdomen and appendix. In: Green field LJ, et al. *Surgery: Scientific principles and practice 2nd ed*. Philadelphia Lippincott-Ravan, 12: 646-61.
7. Graffeo CS, Counselman FL (1996). Appendicitis, *Emerg Medical North m*, 14: 653-71.
8. Budd JS, Armstrong C (1987). Role of *Enterobius vermicularis* in the etiology of appendicitis. *Br J Surg* Aug, 78(8):74-89.
9. Muller R (2002). *Worms and human disease*. Second edition. *CABi*.
10. Hwang KP, Tsai WS, Lincy Lee N (2002). Detection of *Enterobius vermicularis* eggs in the submucosa of the transverse

- colon of a man presented with colon carcinoma. *Am J Trop Med Hyg*, 67: 546-48.
11. Khiruriiia M (2001). The role of helminthiasis in the etiology of acute appendicitis. PMID: 11763815 [pubmed-index for Medline]
  12. Dorfman S, Talbot IC, Torres R, Cardozo J, Sanchez M (1995). Parasitic infestation in acute appendicitis. *Ann Trop Med Parasitol*, 89, 99-101.
  13. Rueda Perez JM, Cabello Rodriguez M, Somaza de Saint-Palais M, Fernandez Lobato R (1993). Appendiceal disease caused by *Enterobious vermicularis*, presentation of 3 cases. *Rev Esp Enferm Dig*, May, 83(5); 389-91.
  14. Syavashi MR (1997). A survey on the prevalence of histopathological findings of parasitic appendicitis of parasitic origin. The second national congress on Parasitology. Tehran, Iran.