

- 9- Lambert , L.A. (1947): Congenital humeroradial synostosis with other synostotic anomalies. *J. Pediat* 31: 573.
- 10- Lenz , W. and Rehman , I. (1976): Distale Symphalangien mit Humeroradial synostose, Karpal synostosen und Brachyphalangie des Daumens *Z Orthop* 114: 202 - 211
- 11- Maroteaux , P. ; Bouvet J.P. and Briard M.L. (1972): La maladie des synostoses multiples. *Nouv. Presse Med.* 16: 3041 - 3047.
- 12- Miller , E.M. (1922): Congenital ankylosis of hands and feet. *J. Bone Jt Surg.* 4: 560.
- 13- Orth , H. (1930): Kongenitale doppelseitige Ankylose beider Ellenbogengelenke. *Inaug - Diss., Bonn.*
- 14- Slater , P. and Rubinstein , H. (1942): Aplasia of interphalangeal joints associated with synostosis of carpal and tarsal bones. *Quart. Bull. Sea View Hosp.* 7: 429.
- 15- Sugiura , Y. and Inagaki ,Y. (1981): Symphalangism associated with synostosis of carpus and / or tarsus. *Jpn. J. Hum. Genet.* 26: 31-45.
- 16- Volkmann, R. (1873): Ein Fall von kongenitaler Luxation beider sprunggelenke. *Deut. Z. Chirurgie* 2: 538-542.

Table 1 - Distribution of affected and non affected individuals in both sexes in large Iranian family with severe multiple synostosis.

	Affected	Non Affected	Total	Penetrance %
Male	28	31	59	90
Female	30	14	44	214
Total	58	45	103	129
Male/Female	93	221	134	

Reference

- 1- Brdiczka , G. (1938): Vererbare und angeborene multiple synostosen an zahlreichen Gelenken der oberen und unteren Extremitäten. Fortschr. Rontgenstr. 58,228.
- 2- Czeizel , A. ; Bod , M. and Lenz , W. (1983): Family study of congenital limb reduction abnormalities in Hungary 1975 - 1977. Hum Genet 65: 34-45.
- 3- Engel , H. (1902): Über kongenitale Ankylosen an den Gelenken der Hände und Füße. Inaug. Diss., Berlin.
- 4- Farhud , D.D. (1985): Presentation of a pedigree with brachydactyly , synostosis of elbow and feet bones in Iran. 19. Tagung der Deutsche Gessellschaft für Anthropologie und Humangenetik. 16-19 Okt. 1985, München, Deutschland.
- 5- Frostad , H. (1940): Congenital ankylosis of the elbow joint. Acta Orthop Scand 11: 296.
- 6- Fuhrmann , W.; Rompe , G. and Steffens , Ch. (1966): Dominant erbliche doppelseitige Dysplasia und Synostose des Ellenbogengelenkes mit symmetrischer Brachymesophalangie sowie Synostosen im Finger-, Hand- und Fußwurzel-bereich. Humangenetik 3: 64.
- 7- Kindl , S. (1907): Fünf Fälle von angeborenen Defektbildungen der Extremitäten. Z. Heilkd. 28; N.F. 8: 110-138.
- 8- Klaussner , F. (1900): Über Missbildungen der menschlichen Gliedmassen und ihre Entstehungsweise. J. F. Bergmann, Wiesbaden, S. 1-151.

Aknowledgment

The author is thankful to Dr. H. Sadighi (Genetic Clinic , Tehran) , for his kind assistance ; also high appreciations to the late Prof. W. Lenz (Munster , Germany) and Prof. Majewski (Dusseldorf , Germany) for their very fruitful consultations.

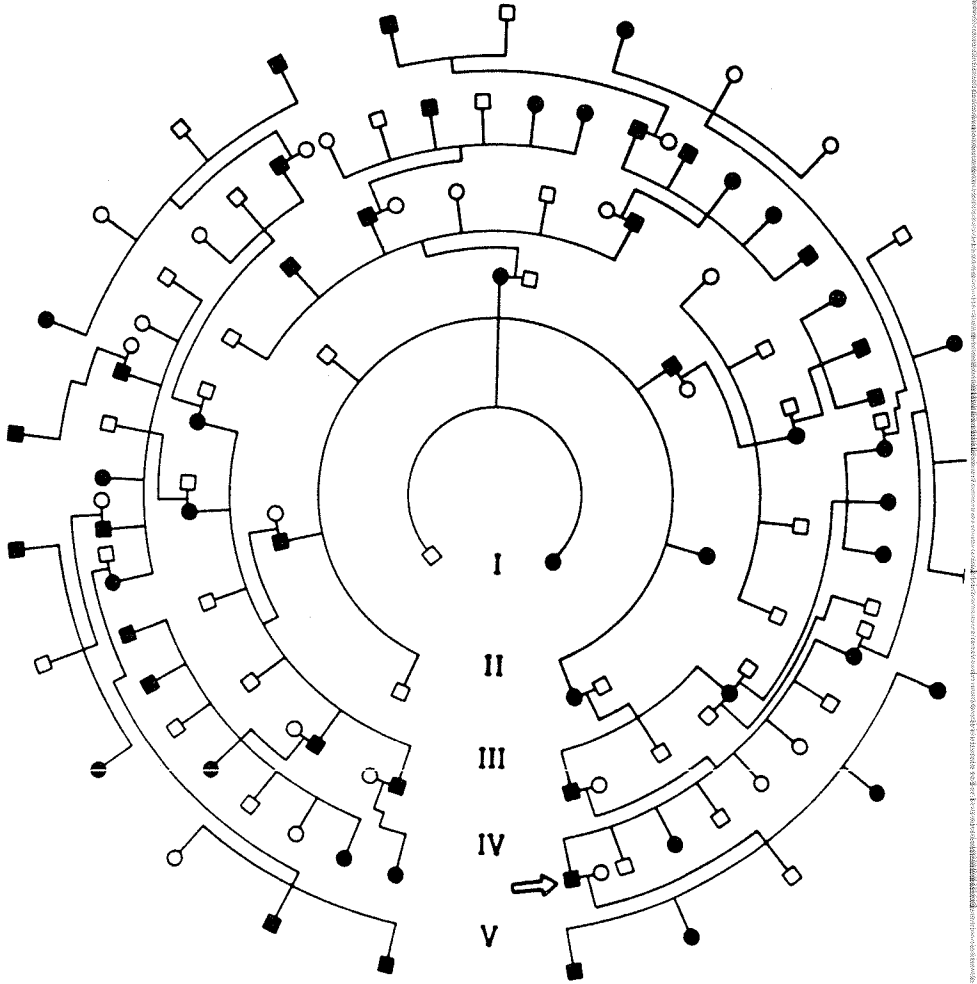


Figure 1 : Pedigree of severe multiple synostosis in large Iranian family

position, because of partial synostosis (physis) of calcaneus and talus, causing a very difficult walking style, on the external cant of the feet.

Fingers have only two segments which appear as brachydactyly. The synostosis of humerus to ulna, fixed in an angle of 110° to 140° of flexion - supination position, limits the movement on elbow in any direction, causing particularly difficult life style, specially in the hand to face/mouth movements causing some adaptive changes in shoulder joints and neck vertebrae, in order to take care of daily activities, resulting anatomical and physiological changes. Also, disuse atrophy of most muscles involved, specially in hands, produce compensatory hypertrophy of some others.

A limitation of supination and pronation in the wrist of both sides are notable in most individuals, and aplasia on distal end segment of 4th phalanges in some affected persons.

Also, several minor anomalies, such as hyperplasia of the humerus, shortness of toes and thumbs, were seen.

The minor anomalies vary on form and intensity in each individuals. Arrangement of a table, with the data from all affected persons, can not be very helpful in this stage.

Figure 1 shows the pedigree of the severe multiple synostosis (a new autosomal dominant syndrome) in an Iranian large family with 103 members (58 affected) in five generation, with full penetrance.

Table 1 shows the distribution of the affected individuals in both sexes. The table also shows a very low number of healthy females in comparison to healthy male (14/31) but the distribution of affected individual are the same in both sexes, with a penetrance of 100%.

An earlier investigation on distal symphalangia with humeroradial and carpal synostosis (10) and another study of symphalangism associated with synostosis of carpus and / or tarsus (15) differ from the features and conditions of this Iranian family.

This large Iranian sibship, was first described in 1985 (4), seems to be affected by a new syndrome. However, further investigations, specially at the molecular level is necessary to confirm this hypothesis.

Introduction

The first report on luxation of toe bones was made in 1873 (16). In 1900 an extensive description of joint malformation and their causes was given (8). A more specific investigation was made on congenital ankylosis on hands and feet , in 1902 (3). Five cases of congenital defects of extremities was reviewed in 1907 (7).

Description of multiple synostosis of upper and lower limbs, elbow joint, humeroradial, and carpal/tarsal synostosis were reported by numerous authors (including 1,2,5,6,9,11,12,13,14).

The available literature on multiple synostosis shows that it is distributed in different ethnic groups worldwide, meaning that separate mutations are responsible for the geographic and symptomatic variations of this autosomal dominant disorder.

Material and method

Study of this large Iranian sibship, was started in 1984, with a young unrelated couple (both 29 years old), who have two boys and three girls, aging from 3 months to 8 years old. Only one boy and the mother were healthy, without any defect of their upper and lower limbs; all other four children and the father were affected.

The family came to the Genetic Clinic in Tehran, for counselling, from the northern Iranian region of Nour, in Mazandaran province, near the Caspian sea. Several trips were made to the region to examine the family members to obtain the data and complete the pedigree in a period of about five years.

Results and discussion

As the radiographs show, the affected members of this family have some major abnormalities, such as brachyphalangia of both sides, synostosis of elbow joint , specially humerus and ulna / radius , and talus/calcaneus fusion, on both sides.

All affected individuals present a fixation of the feet in supination

EVIDENCE FOR A NEW AD SYNDROME : REPORT OF A LARGE IRANIAN SIBSHIP WITH SEVERE MULTIPLE SYNOSTOSIS

D.D. Farhud ^{1,2}, MD, PhD, MG

Key words: *AD syndrome, new syndrome, severe multiple synostosis, Iran.*

Abstract

An investigation was carried out on a young unrelated couple, both 29 years old, with two boys and three girls, 3 months to 8 years old. One boy and the mother were healthy, the other four children and the father were affected.

The family, originally from the district of Nour, in northern Iran, near the Caspian sea, was first counselled at the Genetic Clinic in Tehran in 1984. Several trips were made to the location in a period of five years, to examine this large family.

The major anomalies in this family were: brachyphalangia, elbow joint aplasia (humero - radial synostosis, 110 to 140°), carpal/tarsal synostosis and talus / calcaneus fusion.

All affected individuals present a fixation of the feet in supination position and because of partial synostosis (physis) of calcaneus and talus, walked on lateral side with the external cant of the foot.

All deformities were studied by clinical examinations and radiological confirmations, on each affected individual.

1- Department of Human Genetics & Anthropology, School of Public Health, Tehran University of Medical Sciences, P.O. Box. 14155-6446, Terhan, Iran.

2- Genetic Clinic, 16 Keshavarz Blvd., Vallie Assr Sq., Tehran, Iran.