

REPORT OF 10 CASES OF VISCERAL LARVA MIGRANS IN IRAN

MB. Rokni MSPH¹, J. Massoud PhD¹, Gh. Mowlavi¹

Key words: *Toxocariasis, visceral larva migrans, Iran*

Abstract

Toxocariasis or Visceral Larva Migrans (VLM) is a parasitic infection resulting from the invasion of human visceral organs by Nematode larvae of genus *Toxocara* (dog *Ascaris*).

Using gathered information of clinical manifestations, past history, biochemical and hematological tests, Indirect Fluorescence Antibody test (IFA) and follow up of patients, totally 10 human cases (6 males and 4 females) from 1993 to 1995 were diagnosed. The age of patients was between 3 to 52 years, but the most common age was in age group of 0-9 years old. Most of the patients (7 cases) had a previous history of contact with dog. A history of geophagy and contact with cat was noted in patients 4 & 3, respectively. The residential areas of the patients were Guilan, Tehran, Hamadan, Khuzestan, Zanzan and Mazandaran.

All patients showed high peripheral eosinophilia. Leukocytosis, high SGOT, SGPT and serum globulin were observed in 6,3,2 and 6 cases, respectively. Clinical findings were pain, fever, anorexia, dizziness, dyspnea, weight loss, cough, hepatomegaly, splenomegaly and lymphadenopathy.

Introduction

Toxocariasis or Visceral Larva Migran (VLM) is a parasitic infection resulting from the invasion of human visceral organs by Nematode larvae of the genus *Toxocara*, specially *Toxocara canis* in Iran (3). Final host of parasite is dog, and man is infected by the ingestion of embrionated parasite eggs through contaminated soil, vegetables and proximity to dogs and cats.

Location of larvae in different organs causes many disorders including fever, cough, dizziness, dyspnea, general pain, hepatomegaly, splenomegaly,

1- Dept. of Medical Parasitology and Mycology, School of Public Health and Institute of Public Health Research, Tehran University of Medical Sciences, P.O.Box 14155-6446, Tehran, Iran.

eosinophilia, lymphadenopathy and so on (5,6). Clinical manifestations are present in organs such as heart, lung, brain, eye and so on (17). There are three forms of diseases: VLM, Occular larva Migrans (OLM) and inapparent or occult form. The most common type of infection is VLM, which mostly emerge in children (3,6).

The diagnosis of infection, usually based on the clinical presentation of the patient and serologic tests, needle biopsies are not recommended, since the probability of recovering a larva is low and open liver biopsies for the sole purpose of confirming the diagnosis are not justified (12,17).

Prevalence of disease in the world varies from 3.4% in Spain (10) to 57.8% in Malaysia (7). In Iran due to some difficulties of diagnosis, there wasn't a conclusive result and there are only some case reports available (2,4,9,11,14). Infection rate of dogs to *Toxocara canis* varies from 1.35% (15) to 65%(3) in different parts of the country.

Materials and methods

The disease was confirmed by combination of IFA test, clinical manifestations, biochemical and hematological tests, and finally follow up after treatment. The patients have been referred from throughout the country to the section of helminthology, School of Public Health, Tehran University of Medical Sciences.

Past history was taken of each case concerning individual behaviour, life history, residence, etc. IFA test was performed using figured cryocut *T.canis* worm, the parasite was held in a sandwich prepared from the muscles of rabbit abdomen, then 5 micron sections were prepared at -20°C . Antihuman IgG polyvalent conjugate was used as to the labeling the Ab-Ag binding and was diluted in 1:10. The titer for dilution of serum samples was 1:10. Negative and positive control sera were applied as well. Tests of positive results were repeated. Biochemical tests included: Bilirubine, Alkaline Phosphatase, total Protein, serum Albumine and Globulin, SGOT, SGPT and hematological tests were: CBC, Platelet count, ESR, Prothrombine time, Reticulocyte count and total eosinophil count. Biochemical tests and prothrombin time were performed using valuable kits purchases from different companies. Stool exam also was performed by formol-ether concentration method 3 times to reject other parasitic diseases. Regarding to the follow up of the patients all of them were asked to refer to our lab after the necessary

treatment course and required tests and measures were made to determine any recurrence.

Results

From 1993 to 1995, 10 cases of VLM were diagnosed. The characteristics of the cases are given in Table 1. The age of patients at the time of diagnosis was between 3 to 52 years but the most common age was in age group of 0-9 years old. Of these, 6 were males and the remaining 4 were females. A history of previous geophagy, close contact with dogs and cats were in cases 4,7 and 3, respectively. Clinical signs included general pain, fever, cough, dizziness, dyspnea, sweating, pruritus, weight loss and anorexia (Fig. 1). Hepatomegaly, enlargement of abdomen, splenomegaly and lymphadenopathy were noticed (Fig. 1).

Referring to hematological tests in all cases there were an increase in total and relative eosinophil count, the first ranged from 770- 18368/ml and the latter from 10%-82%. Leukocytosis was observed in 6 cases (4 males and 2 females). As to biochemical tests, three tests had greater value than normal range, including SGOT, SGPT and serum globulin in 3,2 and 6 cases, respectively. No significant ova/parasite was seen in stool exams.

Eight patients were followed up after treatment, no recurrence of disease was observed. They were treated with thiabendazol (25 mg/kg b.i.d for 5 days) (12). Other tests showed no significant results.

Discussion

In this study the most cases were observed in age group of 0-9 years old. Basically the rate of infection is often higher in children (3,5,8). In developed and developing countries the prevalence of infection is up to 20% and 60% in children, respectively (3). The patients were mostly young persons in previous studies (2,4,9,11,14). The adult form of disease presented clinically primarily with lung and abdominal complaints, with elevated IgG more than elevated eosinophilia (6). Behavioural disorders and age specificities are factors leading to more infection of children and there is no sterile immunity in adults in strict sense (6,12). In most studies, general pain, irregular fever, nausea, vomiting, anorexia, weight loss are the most common reported manifestations (3,5). and in our study general pain, fever, weight loss, anorexia and so on were common (Fig. 1). The degree of clinical illness depends on larval number and the

type of organ involved, host immune response and reinfection (6). Hepatomegaly was observed in 6 cases (Fig. 1). Generally, hepatomegaly, fever and eosinophilia are three important markers of the disease (3,6,14).

A previous history of contact with dog and cat as well as geophagy are three important risk factors of disease (6,17) which were present in some cases in our study. Generally, of nematodes causing VLM, *Toxocara canis* is the most important (3) and the dog is its main host. Cat, its another host, is the less dangerous, since it burries its stool under the soil (3). As mentioned before, the rate of infection of dogs with *Toxocara canis* is very high in our country and 70% of our patients had a history of previous contact with this animal. In Karaiib islands, where the prevalence of disease is 100%, geophagy is seen in 100% of cases (16). Concerning the patients occupation (Table 1) contact with dog, soil and vegetable (three important sources of infection) is inevitable.

Stool exams totally were negative, since the parasite releases no ova or larva in stool (5). Anemia was absent and it is not an important finding in this disease (3). Leukocytosis was noted in 6 cases, which is an important finding (1). Since the predominant cell in leukocyte infiltration is eosinophil (3), it was increased in all cases, both totally and relative. Eosinophilia, occasionally reaches up to 50-90% and its duration is long, up to 2 years (16).

In this survey there were some abnormalities in biochemical tests. Since larva mostly infected liver, some biochemical test such as SGOT, SGPT and serum globulin are abnormal and show an increase (16). Elevation of gammaglobulins especially IgE and IgG leads to increase of serum globulins (13).

Acknowledgements

We would like to appreciate Mrs. M. Roohnavaz for her kind cooperation in this study.

Table 1- Characteristics of 10 cases of VLM

Case No.	Age (years)	Sex	Contact with dog	Contact with cat	Geophagy	Occupation	Residence
1	18	F	+	+	-	Student	Tehran
2	21	F	+	-	-	"	Khuzestan
3	26	F	+	-	+	Worker	Guilan
4	52	F	-	-	+	Housewife	Tehran
5	3	M	+	-	-	Child	Guilan
6	5	M	+	+	-	"	"
7	8	M	+	-	+	Student	Hamadan
8	34	M	-	+	-	Servant	Mazandaran
9	41	M	+	-	-	Free	Zanjan
10	43	M	-	-	+	Military	Hamadan

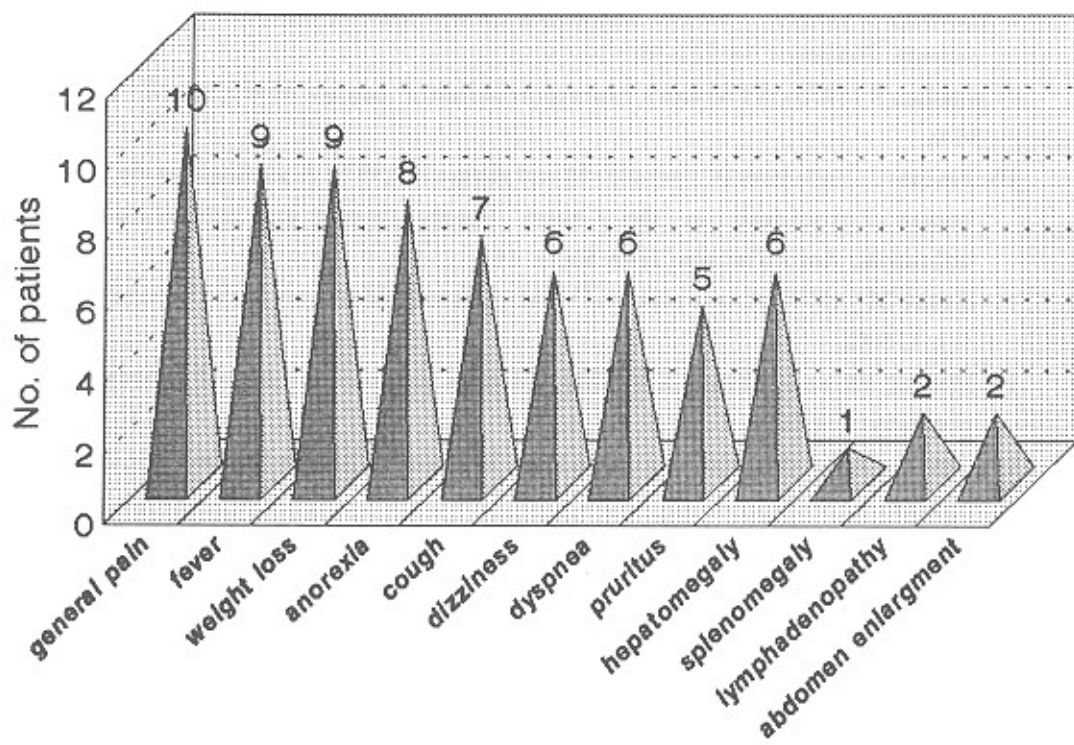


Fig. 1- Frequency distribution of clinical findings in 10 cases with VLM

References

- 1- Arfah F (1989): *Medical Helminthology*, Vol. 2. Banafshe publication : 166-77.
- 2- Bahadori M (1993): A case of VLM. *J Iranian Med Council*, **168**(2): 12.
- 3- Eslami A (1998): *Veterinary Helminthology*. Vol. 3. University of Tehran publication: 133-45.
- 4- Farivar KH and Rafat S (1991): VLM in children and a case report of Zabol. *J Iranian Med Council*, **11**(2): 94-7.
- 5- Fenoy S, Ceuellar C and Guilien G (1997): Serologic evidence of Toxocariasis in patients form Spain with a clinical suspicion of VLM. *JHEL*, **71**:9-12.
- 6- Freedman D and Birmingham A (1997): *Immunopathogenetic aspect of diseases induced by helminth Parasites*, Karger publication: 99-119.
- 7- Hakim S, Thadsavanth M and Shamilah R (1997): Prevalence of *Toxocara canis* antibody among children with bronchial asthma in Klang hospital Malaysia. *Trans Roy Soc Tro Med Hyg*, **91**(5): 528.
- 8- Hunteley C (1965): Clinical characteristics and immunological studies in 51 patients. *Pediatrics*, **36**:523-36.
- 9- Jamalian R (1976): VLM and a case report in Iran. *J Iranian Med Council*, **10**: 36-9.
- 10- Jimenes J, Valladares B, Ferhadez M and Armas F (1997): A serologic study of human Toxocariasis in the Canary islands (Spain) and invironmental influences. *Am J Tro Med Hyg*, **56**(1): 113.
- 11- Kabiri M (1977): A case report of VLM. *J Faculty Med Iran, Meli University*, (1): 136-40.
- 12- Markell Ek and Edward K (1999): *Medical parasitology*. 8th ed. Saunders company: 274-5.
- 13- Obvalier A (1998): Toxocara infestations in humans. *Parasite Immonology*, **20**: 311-17.
- 14- Samar G (1997): A picture of VLM. Paper abstract in 2nd congress of parasitic diseases of Iran: 20.
- 15- Sharifi I (1994): The prevalence of intestinal helminths in stray dogs in Kerman city. *Iranian J Publ Health*, **23**(1-4): 13-23.
- 16- Thompson (1986): *BULL/WHO*. **64**(2): 238-40.
- 17- Yezid G (1989): *Diagnostic pathology of parasitic infection with clinical correlations*: 262-72.