



Morphological Analysis of the Temporomandibular Joint in Patients with Malocclusion Using 2D and 3D Measuring Methods

*Eun-Young JEON, Hyun-Na AHN, *Jong-Tae PARK*

Department of Oral Anatomy, Dankook University College of Dentistry, Cheonan, South Korea

***Corresponding Author:** Email: jongta2@dankook.ac.kr

(Received 19 Mar 2019; accepted 04 Apr 2019)

Dear Editor-in-Chief

Quantitative measurements of the morphological parameters of the Temporomandibular Joint (TMJ) will provide a better understanding of the structure and function of the TMJ in the field of orthodontics for patients with malocclusion (1). A 3D model reconstructed from 2D CBCT scans can be reproduced with a size and volume that are identical to the actual anatomical values, and can provide measurements that are more accurate than simple linear measurements obtained from 2D CBCT scans alone (2). Although there have been efforts to standardize 3D measurements of the TMJ, the differences between 2D CBCT and 3D measurements remain unclear (1).

In this study, subjects were divided into groups with malocclusion of Classes I, II, and III according to the ANB angle and molar occlusal relationships as evaluated by an orthodontist. CBCT scans were obtained in the Digital Imaging and Communications in Medicine (DICOM) format. The 2D CBCT images were measured in accordance with the method by previous research (Fig. 1), (3). For the 3D model measurements, the DICOM files were imported into Mimics software (Materialise, Leuven, Belgium), and the skull was reconstructed into a 3D model to measure the coronal condylar width (CCW), coronal condylar angle (CCA), horizontal condylar angle (HCA), and sagittal ramus angle (SRA) (Fig. 2).

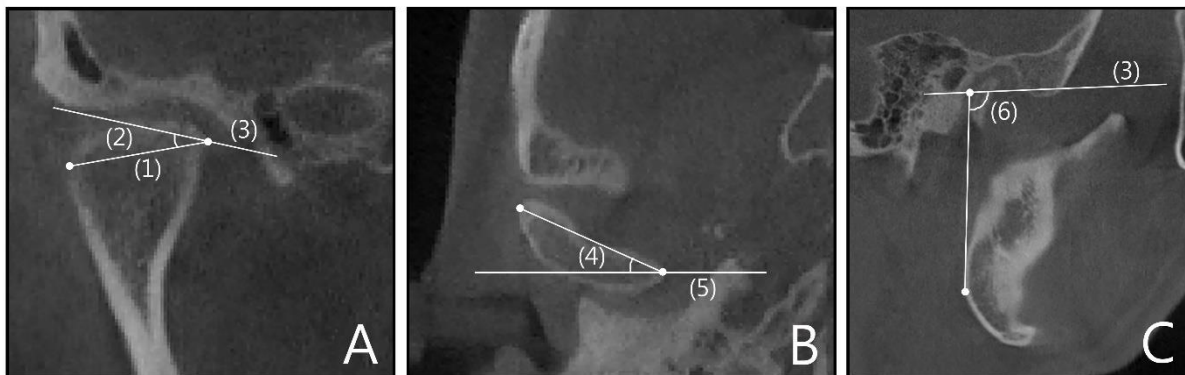


Fig. 1: Measurements of TMJ in 2D CBCT images (A. coronal view, B. horizontal view, C. sagittal view, (1). CCW, (2). CCA, (3). Frankfort Plane, (4). HCA, (5). Right-Left line, (6). SRA)



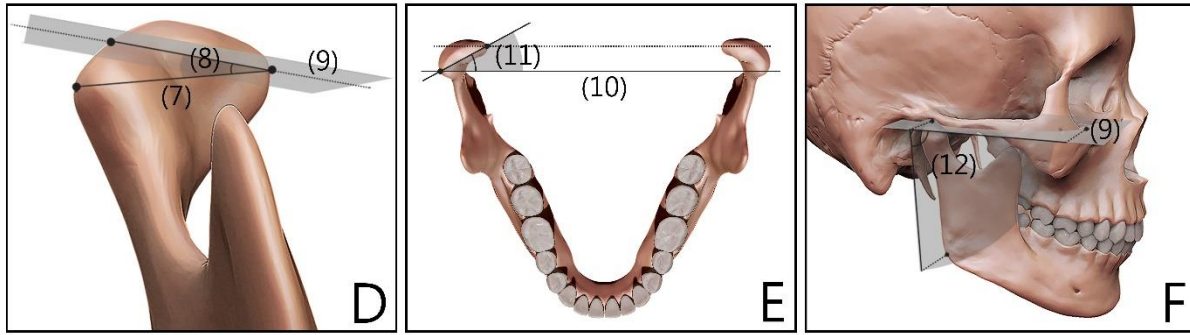


Fig. 2: Measurements of TMJ in 3D models (D. coronal view, E. horizontal view, F. sagittal view, (7). CCW, (8). CCA, (9). Frankfort Plane, (10). Right-Left line, (11). HCA, (12). SRA)

Informed consent was taken for all subjects before the study.

The SPSS, version 20.0, IBM, USA was used for statistical analyses. One-way ANOVA was used to analyze TMJ morphology according to the type of malocclusion. Independent-samples *t*-tests were used to investigate differences according to the measuring method.

The 2D analysis of TMJ morphology according to the type of malocclusion revealed significant differences in the left and right CCW (both $P < 0.001$), HCA ($P = 0.001$ and $P < 0.001$), and SRA (both $P < 0.001$). A post-hoc analysis showed that the CCW and HCA differed significantly between Class II and Classes I and III. While the SRA differed significantly between Class III and Classes I and II. In the 3D model analysis, signif-

icant differences were found between the left and right CCW ($P = 0.009$, $P = 0.038$), CCA ($P = 0.003$, $P = 0.004$), HCA (both $P < 0.001$), and SRA (both $P < 0.001$). In a post-hoc analysis, the CCW differed significantly between Class II and Class III, while the CCA differed significantly between Class I and Class II. The HCA differed significantly between Class II and Classes I and III. The SRA differed significantly between Class III and Classes I and II. The analysis of TMJ morphology according to the measuring method showed significant differences in the left CCW ($P = 0.009$, $P < 0.001$, and $P = 0.001$), the right CCW ($P = 0.001$, $P < 0.001$, and $P = 0.003$), both CCA (all $P < 0.001$), and SRA (all $P < 0.001$) in all of the experimental groups (Table 1).

Table 1: Morphometric analysis of TMJ

Measurement		Mean(SD)	<i>t</i>	<i>P</i>	<i>F</i>	<i>P</i>	<i>P</i> (1,2)	<i>P</i> (1,3)	<i>P</i> (2,3)	
L.CCW	ClassI	2D	18.53(2.43)	-2.765	.009*	9.773	<.001**	.003***	1.000	<.000***
		3D	20.71(2.56)							
	ClassII	2D	15.50(2.93)	-4.002	<.001*					
		3D	19.42(3.26)							
	ClassIII	2D	19.14(2.97)	-3.605	.001*					
		3D	22.19(2.35)							
L.CCA	ClassI	2D	19.19(3.12)	-11.49	<.001*	0.810	0.450	1.000	1.000	0.675
		3D	31.28(3.52)							
	ClassII	2D	19.63(5.10)	-15.81	<.001*					
		3D	39.26(2.20)							
	ClassIII	2D	17.93(4.68)	-15.47	<.001*					
		3D	39.97(3.41)							
L.HCA	ClassI	2D	13.47(2.60)	-1.97	0.057	52.486	<.001**	<.000***	0.807	<.000***
		3D	14.91(1.98)							
	ClassII	2D	21.00(3.68)	-1.64	0.109					
		3D	22.60(2.30)							
	ClassIII	2D	12.46(2.14)	-0.79	0.433					
		3D	13.18(3.51)							
L.SRA	ClassI	2D	75.51(5.31)	-8.91	<.001*	22.740	<.001**	.009***	<.000***	<.000***

		3D	87.75(3.10)			27.268	<.001**	1.000	<.000***	<.000***
	ClassII	2D	79.36(5.16)	-6.19	<.001*					
		3D	87.91(3.39)							
	ClassIII	2D	67.88(5.95)	-7.20	<.001*					
		3D	80.12(4.75)							
R.CCW	ClassI	2D	18.43(2.35)	-3.44	.001*	11.939	<.001**	.001***	1.000	<.000***
		3D	20.99(2.35)			3.469	.038**	0.258	1.000	.037***
	ClassII	2D	14.54(3.89)	-4.71	<.001*					
		3D	19.60(2.83)							
	ClassIII	2D	19.00(2.97)	-3.15	.003*					
		3D	21.66(2.32)							
R.CCA	ClassI	2D	19.47(3.57)	-13.72	<.001*	2.864	0.065	1.000	0.321	0.070
		3D	33.86(3.04)			14.718	<.001**	<.000***	.006***	0.103
	ClassII	2D	20.37(4.59)	-15.10	<.001*					
		3D	39.46(3.31)							
	ClassIII	2D	17.34(4.13)	-16.43	<.001*					
		3D	37.20(3.49)							
R.HCA	ClassI	2D	13.19(2.01)	-1.66	0.105	57.815	<.001**	<.000***	0.207	<.000***
		3D	14.21(1.89)			75.624	<.001**	<.000***	0.522	<.000***
	ClassII	2D	20.68(3.66)	-1.14	0.262					
		3D	21.76(2.15)							
	ClassIII	2D	11.51(2.70)	-1.82	0.076					
		3D	13.16(3.04)							
R.SRA	ClassI	2D	74.91(4.44)	-10.33	<.001*	25.174	<.001**	0.055	<.000***	<.000***
		3D	87.57(3.22)			30.527	<.001**	1.000	<.000***	<.000***
	ClassII	2D	78.77(4.77)	-7.15	<.001*					
		3D	88.11(3.38)							
	ClassIII	2D	67.68(5.74)	-7.15	<.001*					
		3D	79.61(4.76)							

* Independent t-test/** one-way ANOVA/***/ bonferroni. $P < 0.05$

TMD diagnoses have generally been based on 2D CBCT and clinical experience. However, significant differences existed in the morphological parameters measured in two dimensions and those measured in three dimensions (1,2). The results of the present study have demonstrated that a 3D model can provide useful information about the 3D structure of the TMJ and allow more-accurate measurements to be made, which will be useful when evaluating the morphology of the TMJ.

Conflict of interest

The authors declare that there is no conflict of interest.

References

1. Zhang Y, Xu X, Liu Z (2017). Comparison of Morphologic Parameters of Temporomandibular Joint for Asymptomatic Subjects Using the Two-Dimensional and Three-Dimensional Measuring Methods. *J Healthc Eng*, 2017: 5680708.
2. Zhang YL, Song JL, Xu XC, et al (2016). Morphologic analysis of the temporomandibular joint between patients with facial asymmetry and asymptomatic subjects by 2D and 3D evaluation: a preliminary study. *Medicine (Baltimore)*, 95(13): e3052.
3. Ueki K, Moroi A, Sotobori M, et al (2012). Changes in temporomandibular joint and ramus after sagittal split ramus osteotomy in mandibular prognathism patients with and without asymmetry. *J Craniomaxillofac Surg*, 40(8): 821-27.