



Comparison of the Joint Space in Different Types of Malocclusion Using Three-Dimensional Models

*Eun-Young JEON¹, Jeong-Hyun LEE², *Jong-Tae PARK²*

1. Department of Dental Hygiene, Kyung Bok University, Namyangju, South Korea
2. Department of Oral Anatomy, College of Dentistry, Dankook University, Cheonan, South Korea

*Corresponding Author: Email: jongta2@dankook.ac.kr

(Received 09 Feb 2019; accepted 22 Feb 2019)

Dear Editor-in-Chief

Harmonious functioning of the temporomandibular joint (TMJ) is crucial to the correct operation of the masticatory system, which makes ideal positioning of the condyle in the TMJ clinically important (1). The joint space is determined by the size of the glenoid fossa and condyle and the position of the condyle within the glenoid fossa (2), and so the joint space is used as a marker to assess condylar positioning in the glenoid fossa (3). Many studies have analyzed the joint space in patients with malocclusion (4-5). 2D techniques cannot accurately measure the narrow 3D joint space. Therefore, 3D models are more appropriate for joint-space measurements (6).

This study was approved by the Institutional Review Board of Dankook University Dental Hospital (DUDH IRB 2015-12-022).

CBCT data were obtained for 60 patients admitted to the Orthodontics Divisions in the Department of Oral and Maxillofacial Radiology at Dankook University. The CBCT data of 60 patients with malocclusion were obtained in the Digital Imaging and Communications in Medicine (DICOM) format from a CBCT scanner (Alphard 3030, Asahi, Kyoto, Japan). The DICOM files were imported into Mimics software (Materialise, Leuven, Belgium) for constructing 3D models of the skull. Since the joint space corresponds to an empty space, the Mimics files of the 3D-reconstructed skulls were imported into

Freeform software (3D Systems, Rock Hill, SC, USA) to allow accurate measurements to be made. Areas corresponding to the condyle, fossa, and joint space were cropped out, and the area corresponding to the joint space was filled to construct a 3D model. We reconstructed the CBCT data of patients with malocclusion of classes I, II, and III as 3D models and measured the joint space at different locations to facilitate comparisons of the spatial properties of the TMJ Figs. 1, 2.

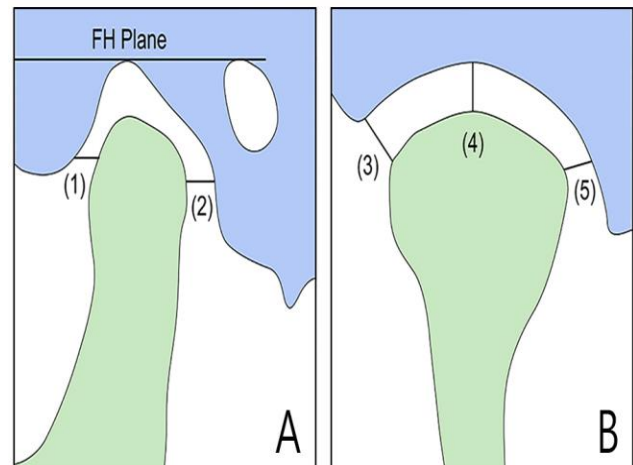


Fig. 1: Measurements of joint space (A. sagittal view, B. coronal view, (1). AJS, (2). PJS, (3). LJS, (4). SJS, (5). MJS)

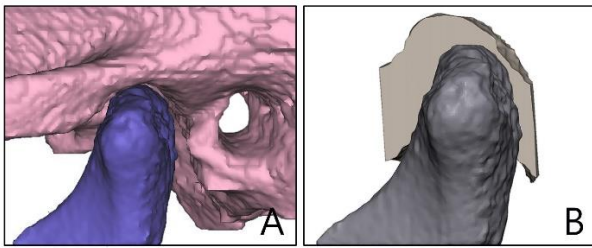


Fig. 2: 3D models of patients with malocclusion (A. reconstruct from mimics program, B. reconstruct from freeview program)

A Kruskal-Wallis test was used to analyze the joint space according to different types of malocclusion. Significant differences in the measured left and right joint-space values were found be-

tween the three experimental groups: in the anterior joint space (AJS) ($\chi^2=12.473$ and $P=0.002$ on the left, and $\chi^2=7.868$ and $P=0.020$ on the right), superior joint space (SJS) ($\chi^2=18.565$ and $P<0.001$, and $\chi^2=13.937$ and $P=0.001$, respectively), and lateral joint space (LJS) ($\chi^2=8.237$ and $P=0.016$, and $\chi^2=9.463$ and $P=0.009$, respectively). A significant interclass difference was observed for the left medial joint space (MJS) ($\chi^2=11.878$, $P=0.003$). A post-hoc Mann-Whitney U test adjusted using the Bonferroni correction method revealed significant differences in the left and right AJS, SJS, LJS, and left MJS measurements (Table 1).

Table 1: Average rank and result of kruskal wallis test of joint space measurements of subjects in three subgroup

Measurements		Mean number	Chi-square	P-value	B.C. method
LAJS	ClassI	19.60	12.473	0.002*	Class I <class II, III
	ClassII	33.50			
	ClassIII	38.40			
LPJS	ClassI	32.10	1.637	0.441	-
	ClassII	32.95			
	ClassIII	26.45			
LSJS	ClassI	31.35	18.565	0.000**	ClassIII<class I , class II
	ClassII	41.95			
	ClassIII	18.20			
LLJS	ClassI	30.45	8.237	0.016*	ClassIII<class II
	ClassII	38.45			
	ClassIII	22.60			
LMJS	ClassI	29.20	11.878	0.003*	ClassIII<class II
	ClassII	40.60			
	ClassIII	21.70			
RAJS	ClassI	22.45	7.868	0.020*	Class I <class II
	ClassII	37.90			
	ClassIII	31.15			
RPJS	ClassI	25.40	2.591	0.274	-
	ClassII	33.55			
	ClassIII	32.55			
RSJS	ClassI	36.20	13.937	0.001**	ClassIII<class I , class II
	ClassII	36.70			
	ClassIII	18.60			
RLJS	ClassI	29.50	9.463	0.009*	ClassIII<class II
	ClassII	39.45			
	ClassIII	22.55			
RMJS	ClassI	34.25	2.004	0.367	-
	ClassII	26.45			
	ClassIII	30.80			

* P-value were obtained by Kruskal-Wallis($P<0.05$)

** P-value were obtained by Kruskal-Wallis($p<0.001$)

The same characters were not significant by bonferroni correction method(B.C. Method)/ $.05/3=0.167$

The joint space is constituted empty space using 3D models (6). However, measuring the joint space between the glenoid fossa and condyle using 3D software requires a connection between the outermost edge of the condyle, used as a reference point, and the innermost edge of the glenoid fossa. The PJS and AJS must be measured parallel to the Frankfort plane, and considerable interexaminer errors arise during this process. To overcome these limitations, the present study filled the joint space using Freeform software before measuring it. We found that the measured joint space varied with the type of malocclusion. The obtained results will provide deeper insights into malocclusion and TMJ shapes, and suggest that malocclusion can contribute to TMJ deformation.

Acknowledgements

This work was supported by a National Research Foundation of Korea Grant funded by the Korean Government (NRF 2016R1D1A1B01008853).

Conflict of interest

The authors declare that there is no conflict of interest.

References

1. Dalili Z, Khaki N, Kia SJ, Salamat F (2012). Assessing joint space and condylar position in the people with normal function of temporomandibular joint with cone-beam computed tomography. *Dent Res J*, 9(5): 607-12.
2. Stuart CW, Michael JP (2009). *Diagnostic Imaging of Temporomandibular Joint: Oral radiology - principles and interpretation*. 6th ed. Mosby Publishers. Missouri.
3. Panchbhai AS (2017). Temporomandibular joint space. *Indian J Oral Health Res*, 3(2): 47-56.
4. Paknahad M, Shahidi S, Akhlaghian M, Abolvaradi M (2016). Is mandibular fossa morphology and articular eminence inclination associated with temporomandibular dysfunction?. *J Dent (Shiraz)*, 17(2): 134-41.
5. Arieta-Miranda JM, Silva-Valencia M, Flores-Mir C, Paredes-Sampen NA, Arriola-Guillen LE (2013). Spatial analysis of condyle position according to sagittal skeletal relationship, assessed by cone beam computed tomography. *Prog Orthod*, 14(1): 36-44.
6. Zhang YL, Song JL, Xu XC, et al (2016). Morphologic analysis of the temporomandibular joint between patients with facial asymmetry and asymptomatic subjects by 2D and 3D evaluation: a preliminary study. *Medicine (Baltimore)*, 95(13):e3052.