



A Case of Hepatic Fasciolosis Presented with Prolonged Fever in Southern Iran

Anahita SANAEI DASHTI¹, Amir NASIMFAR², *Alireza SHOWRAKI³, Bita GERAMI-ZADEH⁴

1. *Alborzi Clinical Microbiology Center, Namazi Hospital, Shiraz University of Medical Sciences, Shiraz, Iran*
2. *Pediatric Department, Namazi Hospital, Shiraz University of Medical Sciences, Shiraz, Iran*
3. *School of Medicine, Shiraz University of Medical Sciences, Shiraz, Iran*
4. *Pathology Department, Namazi Hospital, Shiraz University of Medical Sciences, Shiraz, Iran*

***Corresponding Author:** Email: ali66sh@gmail.com

(Received 19 Aug 2014; accepted 25 Nov 2014)

Abstract

Background: Human fasciolosis is deemed as an emerging/re-emerging infection, hence making it an important human parasitic disease. In contrast to northern parts of Iran, human cases of fasciolosis in southern Iran are rare and sporadic. We report a sporadic case of fasciolosis in southern Iran (Fars Province) who presented with prolonged fever. Our report could suggest that there might be new foci emerging in the region, which indicates the need for further investigations.

Keywords: Fasciolosis, Southern Iran, Prolonged Fever

Introduction

Human fasciolosis is currently considered as an emerging/re-emerging infection, hence making it an important human parasitic disease (1). An estimation of 2.4 million human cases in 61 countries and 180 million inhabitants at risk (1) raises an alarming concern about its future prevalence. The critical changes seen in the epidemiological figures of human fasciolosis in the past four decades urges the need for further studies in different aspects of the disease. Along with the increase in the prevalence of human fasciolosis, the clinical suspicion should also be heightened even in non-endemic areas. Northern Iran, where the biggest outbreak of human fasciolosis in the world occurred in 1987-97 (2), is one of the well-known regions for fasciolosis. However, southern Iran is not recognized as an endemic region and only sporadic cases were reported in the past several years.

We present a 16 year old boy from southern Iran who presented with prolonged fever (fever of unknown origin: FUO) and was ultimately diagnosed with fasciolosis. We believe that this case report could suggest that there might be new or unfound foci in the region, which calls the need for further investigation.

Case Description

We present a case of a 16-year-old boy from southern Iran who presented primarily with fever for more than four weeks. He was admitted at hospital as a case of FUO (Fever of unknown origin). His fever was accompanied by mild epigastric abdominal pain, weight loss (~ 20%) and night sweats. Physical examination was unremarkable except for a large liver size (~ 3 cm below costal margin in mid-clavicular line).

Preliminary laboratory studies exposed marked eosinophilia (7900 /mm³ White Blood Cells with dominance of eosinophils [~ 40%]) and abnormal liver function tests (marked elevation of alkaline phosphatase [ALP=813 u/l], slight increase in as-

partate aminotransferase [AST=51 u/l] and alanine aminotransferase [ALT=65 u/l]). Other extensive laboratory and para-clinical studies are demonstrated in Table 1.

Table 1: Laboratory and para-clinical studies and their results

| Laboratory tests | Results | Para-clinical studies | Results |
|----------------------|--------------------------|----------------------------|---|
| White blood cells | 7900 /mm ³ | Peripheral blood smear | Marked eosinophilia |
| | 40% | Abdomino-pelvic Sonography | Hepatomegaly with hypo-echoic areas |
| Eosinophils | 11 g/dl | | |
| Hemoglobin | | | |
| Platelets | 320.000 /mm ³ | Abdomino-pelvic CT scan | Hepatomegaly with hypo-dense areas |
| AST | 51 u/l | Bone marrow biopsy | Moderate hypo cellular marrow with eosinophilia |
| ALT | 65 u/l | | |
| Alkaline phosphatase | 813 u/l | | |
| IgE | 597 IU/ml | | |
| Stool exam (x 3) | Negative | Liver needle biopsy | Marked Portal eosinophilic infiltration |

Subsequent investigation by abdomino-pelvic CT scan revealed multiple hypo dense areas in the liver (especially in the liver periphery, Fig.1). Liver needle biopsy was taken from these lesions, which showed marked portal eosinophilic infiltration (Fig. 2). Due to the patient marked eosinophilia, there was a great suspicion toward parasitosis. However, multiple stool exams (both wet and concentrated smears) for detection of pathogenic parasites were negative. In accordance with of our

high index of suspicion toward a parasitic cause and considering some sporadic reports of fasciolosis in southern Iran, we ultimately performed a serological test (Indirect ELISA test) for *Fasciola hepatica* (positive result).

Eventually with a diagnosis of fasciolosis, the patient received a single dose of triclabendazole (10 mg/kg) which subsequently led to rapid alleviation of symptoms.

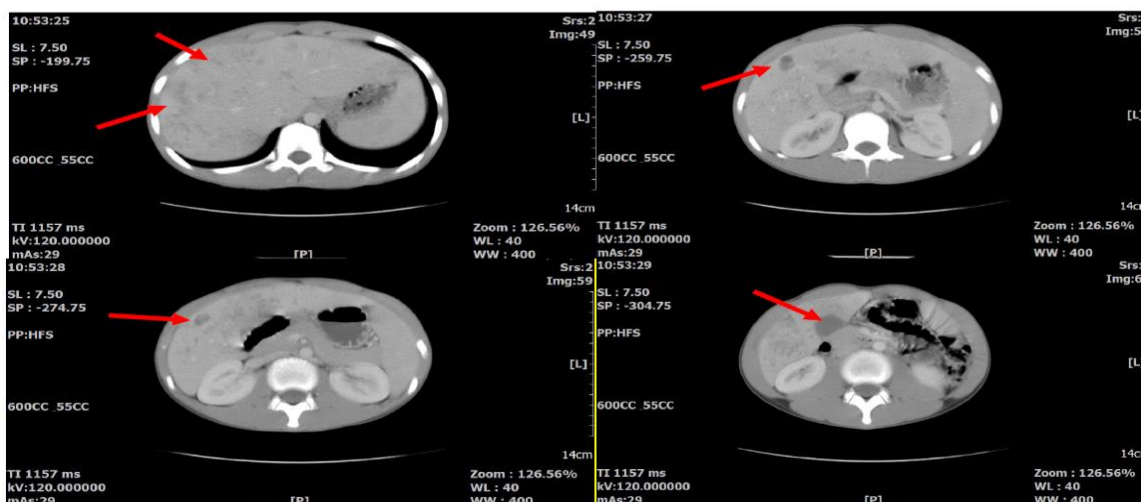


Fig. 1: Abdomino-Pelvic CT scan (axial view) revealing multiple hypo-dense areas in the liver

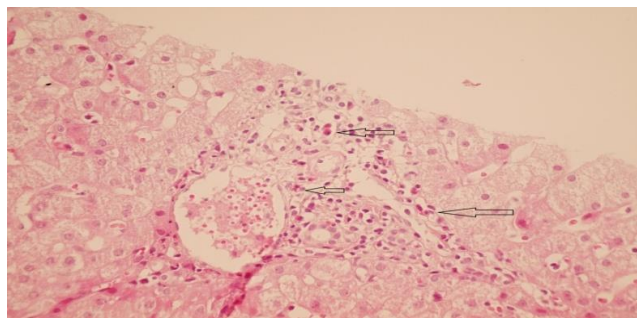


Fig. 2: Sections from the liver show heavy infiltration of eosinophils. (H&E X250)

Discussion

Fasciolosis is an important parasitic disease, not only as a public health concern but also as a factor in hampering economic growth (due to involvement of livestock). The global economic loss is estimated to be over 2 billion US\$ annually (3), making fasciolosis a major global burden.

Although humans are accidental hosts and fasciolosis was traditionally considered rare, recent estimates indicate that millions of people are at risk of fasciolosis (3). Interestingly the analysis of the global geographical distribution of human fasciolosis revealed that the anticipated correlation between human and animal fasciolosis appears just at basic levels (3), hence making the epidemiological relations more complex.

Prior to 1988, only sporadic cases of human fasciolosis were reported in Iran with an approximate annual rate of 100 cases (1). In 1988, the greatest outbreak of fasciolosis in the world occurred in northern Iran (Gilan province) affecting more than 10,000 individuals (4). Since then at least 17,000 human cases has been reported from Gilan province, therefore making northern Iran as an endemic area for the disease (5). Interestingly, although the prevalence of animal fasciolosis is the same or even higher in southern Iran, the prevalence of human fasciolosis is significantly higher in Northern parts of the country.

In the past several years new cases of human fasciolosis is being reported in southern areas of the country (2) insinuating the probable fact of emerging new foci. Sarkari et al. demonstrated a high sero-prevalence of human fasciolosis in

southwest of Iran (Yasuj district) and considered the area as a potential new emerging focus of the disease in Iran (2). Alavi-Naini et al. reported a case of fasciolosis in southeastern Iran, presented as chronic cholecystitis (6).

In contrast to northern parts of Iran, human cases of fasciolosis in southern Iran are rare and sporadic. Therefore, the occurrence of even one human fasciolosis is of great importance. We report a sporadic case of fasciolosis in southern Iran (Fars Province) who presented with prolonged fever (FUO). Our report could suggest that there might be new foci emerging in the region, which indicates the need for further investigations. We also emphasize that in any patient with non-specific symptoms and significant eosinophilia, fasciolosis should not be neglected.

Acknowledgements

The authors declare that there is no conflict of interests.

References

1. Salahi-Moghaddam A, Arfaa F (2013). Epidemiology of Human Fascioliasis Outbreaks in Iran. *J Arb Mil Med*, 1(1): 6-12.
2. Sarkari B, Ghobakhloo N, Moshfeaa AA, Eilami O (2012). Seroprevalence of Human Fasciolosis in a New-Emerging Focus of Fasciolosis in Yasuj District, Southwest of Iran. *Iran J Parasitol*, 7(2):15-20.
3. Chen J-X, Chen M-X, Ai L, Xu X-N, Jiao J-M, Zhu T-J, Su H-Y, Zang W, Luo J-J, Guo Y-H, Lv S, Zhou X-N (2013). An Outbreak of Human *Fascioliasis gigantica* in Southwest China. *PLoS ONE*, 8(8): e71520. doi:10.1371/journal.pone.0071520.
4. Assmar M, Forghan-Parast K, Yadegari D (1990). Report of fascioliasis epidemic in Gilan province. *First national congress of parasitic disease in Iran*, 1990; Iran. 81 p.
5. Rokni MB (2008). The present status of human helminthic diseases in Iran. *Ann Trop Med Parasitol*, 102:283-95.
6. Alavi-Naini R, Sharifi-Mood B, Khazaei AR, Khorrami P (2013). A case of fascioliasis from south-east of Iran. *Zabedan J Res Med Sci (ZJRMS)*, 15(12): 40-41.