

## Genetic Analysis of Oculocutaneous Albinism Type1A (OCA1A) in an Iranian Family

H Pour-Jafari<sup>1&2</sup>, A Zamanian<sup>3</sup>, \*B Pour-Jafari<sup>1</sup>

<sup>1</sup>Research Center for Molecular Medicine, Hamadan University of Medical Sciences, Iran

<sup>2</sup>Dept. of Mol Med and Genetic, School of Medicine, Hamadan University of Medical Sciences, Iran

<sup>3</sup>Dept. of Dermatology, School of Medicine, Hamadan University of Medical Sciences, Iran

(Received 23 Apr 2009; accepted 10 Jan 2010)

### Abstract

**Background:** Oculocutaneous albinism type1 (OCA1) is characterized by the absence of melanin pigmentation. The mutation on TYR gene makes OCA1 as an autosomal recessive genetic disorder. In this study, we delineated the genetic analysis of an Iranian family with four members affected with OCA1.

**Methods:** Clinical exams and paraclinical test were performed for all patients of the case family, also proband, her husband, and her parents. Pedigree chart was drawn too. We extracted the genomic DNA from the leukocytes of seven members of the family. Haplotype analysis at the TYR locus was done and informative microsatellite markers were employed. In order to amplify the entire coding region of the TYR gene, for bidirectional direct sequencing mutation analysis, eight sets of primers were used.

**Results:** Our patients were diagnosed as affected with Oculocutaneous albinism type1a. Analysis of pedigree pattern showed an autosomal recessive inheritance. Analysis with different markers in chromosomes 5, 6, 9, 11 and 15 showed that cause of albinism in our case family was on chromosome 11 (D11S1887 marker was informative).

**Conclusions:** The results offered a more developed method of diagnosis for OCA1 carrier identification and genetic counseling for OCA1 affected families as well; also submit a sample of mutation involved with oculocutaneous albinism in Iran. Genetic analysis is necessary for determining the type of albinism in an individual patient.

**Keywords:** Chromosomes, 11 / Gene, OCA1A /Albinism

### Introduction

Albinism is a heterogeneous group of nonprogressive genetic disorders characterized by complete or partial lack of melanin production in the skin, hair, and/or eyes (1).

Reduction in visual acuity due to the Absence of melanin may occur in some patient (2).

“Oculocutaneous albinism has a wide spectrum; OCA1A is the most severe type with complete melanin reduction and OCA1B, OCA2, OCA3 and OCA4 are the milder types. Although the clinical phenotype of different types of OCA is not always distinguishable, "because of mutations in different genes, making molecular diagnosis is a useful tool and essential for genetic counseling” (2).

“About 1 in 70 people carry a gene for OCA. OCA1 (MIM 203100) is caused by mutations in the tyrosinase gene (TYR, MIM 606933) on chromosome 11q14.3. The gene consists of 5

exons spanning about 65 kb of genomic DNA and encoding a protein of 529 amino acids. TYR (EC 1.14.18.1) is a copper-containing enzyme catalysing the first two steps in the melanin biosynthesis pathway, converting tyrosine to L-dihydroxy-phenylalanine (DOPA) and subsequently to DOPAquinone” (2).

There are two subtype of OCA1; OCA1A and OCA1B. OCA1 is caused by a mutation with complete lack of tyrosinase activity while mutations rendering some enzyme activity result in OCA1B, therefore some melanin pigments are accumulated over time (3).

“Mutations in the OCA2 gene (formerly known as the P-gene) (MIM 203200) cause the OCA2 phenotype (MIM 203200). OCA3 (MIM 203290) is caused by mutations in tyrosinase-related protein 1 (TYRP1, MIM 115501, 9p23)” (2).

“Mutations in the membrane-associated transporter protein gene (*MATP*, also known as *SLC45A2*, MIM 606202) cause OCA4 (MIM 606574)” (4).

Initially there was a report in 1989 for mutation in *TYR* gene (5); almost 200 mutations in *TYR* are known so far (6).

Our findings will indicate the molecular diagnosis of OCA1 and will present mutation in an ethnic group, in another word, will submit the type of mutation presented in an Iranian family.

### **Case presentation**

Nine members from an Iranian family including a young woman III-9 (normal appearance proband), her parents (II-3 and II-4), her four affected sibs (III-12 to III-15), her husband (III-8), and her normal sister in law (III-11) actively involved with the present research work. They took part in our interview about their family history and let us to draw the pedigree chart, clinical examinations. Among them seven members of family let us for blood sampling for tyrosinase activity test and DNA extraction. The nature of the study was discussed for all participants. Research Committee and Ethics Committee of Hamadan University of Medical Sciences approved the study.

### **a) Clinical and Paraclinical findings**

All four affected individuals (one male and three females) were clinically examined. There was no pigmentation in their skin, hair and iris, which were adapted with their birth history. There was no pigmented lesion in their skin, but three of them had melanocytic nevi that were not pigmented. The appearances of their hair were normal but mildly yellowish that was because of protein demolition caused by the sun exposure also effect of chemical detergents. Their irises were not pigmented but seemed blue/grey. Ophthalmic horizontal nystagmus was detected in all of them and their visual acuity was decreased due to the disorder of optic chiasma or fovea hypoplasia. The ophthalmic disorder of our cases was estimated mild to moderate. No sign of malignancy were found in our cases.

Based on such clinical findings classic oculocutaneous albinism (OCA1A) characterized by deficient synthesis of melanin pigment were diagnosed among all of the affected members; in addition, results of tyrosinase activity test were negative for them.

### **b) Family history and pedigree Pattern**

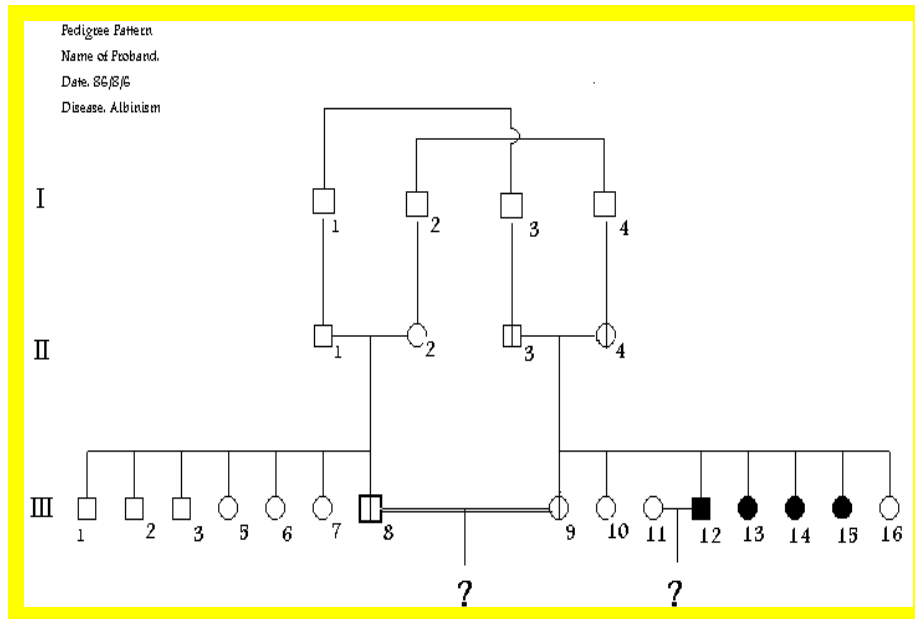
A young couple with consanguinity marriage asked for genetic counseling. They were solicitous to have an albino child in future and wanted to hear an estimation rate for its risk. In addition they wanted more information about prenatal diagnosis. The female partner, aged 20 yr, had one married brother (aged 25 yr) and three sisters, all albino (aged 28, 23 and 18 yr respectively). Also she had two normal appearance sisters (aged 16 and 14 yr) as well as herself and her 22 yr old husband.

They claimed, as they know, there was no any similar condition in their family history (Fig.1).

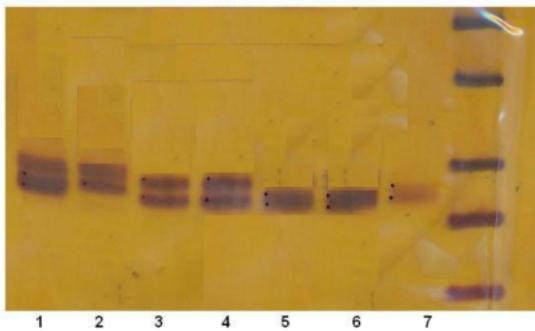
### **C) Molecular analysis**

We extracted the genomic DNA from the peripheral blood leukocytes by salting out method (7). Markers that were used are as follow: D9S1869, D9S269, D6S280, D5S651, D11S1887, D11S1311, D15S165, D15S1002 (8). Based on pedigree analysis, the inheritance pattern of the considered disease in case family was autosomal. So we did not check the sex linked mutation and did not use the related markers, (DXS991, DXS8035, DXS8051, DXS1061).

In addition to clinical findings that were agree with the standard diagnostic criteria, only D11S1887, among the mentioned markers, was informative in DNA samples (Fig. 2). The result of the molecular analysis proved that the disease among three affected members (H., T. and S.) of the considered family, that were agree for sampling, was oculocutaneous type1 (OMIM# 203100) with gene map locus 11q14-q21. Gel analyzing showed that the proband (A.), her husband (M.) and her parents (II-3 and III-4) were heterozygote (carrier) for mentioned mutant gene.



**Fig. 1:** Pedigree pattern of a family with four members affected with oculocutaneous albinism type 1A.



**Fig.2:** Polymerase chain reaction (PCR) analysis in 10% polyacrylamide gel with D11S1887 marker among seven members of the case family. Right lane is DNA molecular marker

1. Father (carrier).
2. Mr. A., Husband (carrier).
3. Mr. H., Brother (affected).
4. Miss T., Sister (affected).
5. Mrs. M., Proband (carrier).
6. Miss S., Sister (affected).
7. Mother (carrier).

## Discussion

There are four recognized types of OCA (OCA1, OCA2, OCA3 and OCA4) that OCA2 is the most frequent type. Diagnose of patients is initially based on the clinical examination because

their phenotype that is totally or partially depigmented (in hair, skin, eyes), they also have ophthalmic nystagmus and reduced visual acuity. In OCA1A tyrosinase is completely inactive and no melanin is produced (9).

In our study the results of tyrosinase activity test of patients that were diagnosed OCA1A clinically, were negative. Also only D11S1887, among our used markers, was informative in DNA samples. The pedigree pattern of the family showed autosomal recessive inheritance for OCA1A and it showed the high risk members to be candidate for carrier identification.

Researchers have reported different mutations related to this type of albinism in different ethnic groups. Thirteen new mutations in the tyrosinase gene were reported in Oetting and colleagues's study including 9 missense mutations (H19Q, R521, R77C, G97R, C289R, L312V, P313R, F340L and H404P), two nonsense mutations (W80X and R116X) and two frameshift mutations (53delG and 223 delG) (10). Also Miyamura and his co-workers reported five novel mutations in tyrosinase gene of patients with OCA1 (11).

Nakamura and colleagues have reported a novel missense substitution, R239W (CGG --> TGG)

of the tyrosinase gene in a patient with tyrosinase-negative OCA (9).

“Tripathi and colleagues presented an analysis of the TYR gene in eight Indo-Pakistani patients with type I OCA. They described four novel TYR gene mutations and a fifth mutation previously observed in a Caucasian patient (12)” that one of those mutations was similar to the mutation that we found among our case family.

“A total of four OCA1 families were perused in India, Haplotype analysis using microsatellite markers (D11S1887 and D11S1311) spanning the TYR locus revealed that the phenotype of three families were consistent with disease segregation at the TYR gene (data not shown). In this study eleven additional markers were used (D5S426, D5S651, D6S280, D9S269, D9S1869, D15S165, D15S1002, DXS991, DXS1061, DXS8035, and DXS8051) to assess other candidate gene loci. No other locus was indicated as being associated with the phenotype in these four OCA1 families. They identified two novel deletions (c.937del8, c.1379del2) and a previously known nonsense mutation (R278X) in the TYR gene from a total of 8 oculocutaneous albinism patients in India (8).”

Specification of the most frequent mutations of a special gene among the affected individuals in a population will decrease the costs for screening of the mutation typing in other families belongs to that population.

In the case family, two couples were eager to know the risk of condition in their future child. The first couple, III-8 and III-9, was high risk for having an affected child, because both of them were carrier. Although one of the partners of the second couple (III-11 and III-12) was affected, there was no risk for having an albino progeny because the other partner has normal alleles.

The results offered a more developed method of diagnosis for OCA1 carrier identification and genetic counseling for OCA1 affected families as well; also submit a sample of mutation involved with oculocutaneous albinism in Iran. Genetic analysis is necessary for determining the type of albinism in an individual patient.

## Acknowledgements

Authors would like to sincerely thank to Dr Masoud Houshmand, Dr Sanati, Mrs Dehghan Man-shadi, Mrs Nooshin Shabab and Mrs Fahimeh Talebzadeh for their very useful helps. The study was granted and approved by Hamadan University of Medical Sciences, Hamadan, Iran.

The authors declare that they have no conflicts of interest.

## References

1. Zuhlke C, Stell A, Kasmann-Kellner B (2007). Genetics of oculocutaneous albinism. *Ophthalmologie*, 104(8) :674-80.
2. Grønskov K, Ek J, Brøndum-Nielsen K (2007). Oculocutaneous albinism. *Orphanet J Rare Dis*, 2: 43.
3. Karaman A (2008). Oculocutaneous albinism type 1A: A case report. *Dermatology Online Journal*, 14(11): 13.
4. Newton JM, Cohen-Barak O, Hagiwara N, Gardner JM, Davisson MT, King RA, Brilliant MH (2001). Mutations in the human orthologue of the mouse underwhite gene (uw) underlie a new form of oculocutaneous albinism, OCA4. *Am J Hum Genet*, 69(5): 981-88.
5. Tomita Y, Takeda A, Okinaga S, Tagami H, Shibahara S (1989). Human oculocutaneous albinism caused by single base insertion in the tyrosinase gene. *Biochem Biophys Res Commun*, 164(3): 990-96.
6. The Human Gene Mutation Database at the Institute Medical Genetics in Cardiff (2009). Available from: <http://www.hgmd.org/>
7. Miller SA, Dykes DD, Polesky HF (1988). A simple salting out procedure for extracting DNA from human nucleated cells. *Nucleic Acids Res*, 16(3): 1215.
8. Sundaresan P, Sil AK, Philp AR, Randolph MA, Natchiar G, Namperumalsamy P (2004). Genetic analysis of oculocutaneous albinism type I (OCA1) in Indian fami-

- lies: two novel frameshift mutations in the *TYR* gene. *Mol Vis*, 10: 1005-10.
9. Nakamura E, Miyamura Y, Matsunaga J, Kano Y, Dakeishi-Hara M, Tanita M, Kono M, Tomita Y (2002). A novel mutation of the tyrosinase gene causing oculocutaneous albinism type I (OCA1). *J Dermatol Sci*, 28(2): 102-5.
  10. Oetting WS, King RA (1992). Molecular analysis of type 1-A (tyrosinase negative) oculocutaneous albinism. *Hum Genet*, 90(3): 258-62.
  11. Miyamura Y, Verma IC, Saxena R, Hoshi M, Murase A, Nakamura E, Kono M, Suzuki T, Yasue S, Shibata S, Sakakibara A, Tomita Y (2005). Five novel mutations in tyrosinase gene of Japanese and Indian patients with oculocutaneous albinism type I (OCA1). *J Invest Dermatol*, 125(2): 397-98.
  12. Tripathi RK, Bunday S, Musarella MA, Droetto S, Strunk KM, Holmes SA, Spritz RA (1993). Mutations of the tyrosinase gene in Indo-Pakistani patients with type I (tyrosinase-deficient) oculocutaneous albinism (OCA). *Am J Hum Genet*, 53(6): 1173-9.